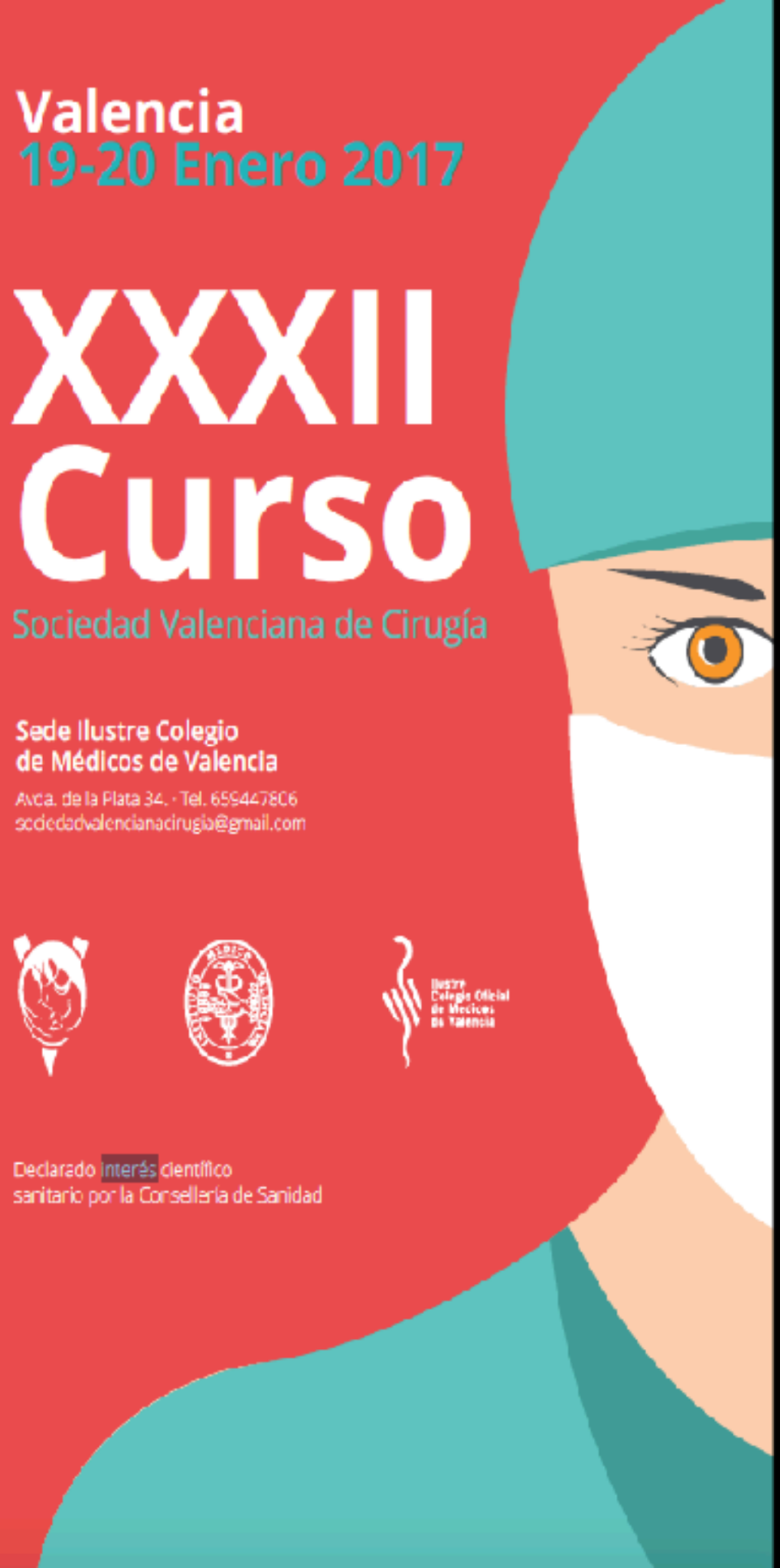

Implicaciones del estudio por imagen en el tratamiento loco-regional del cáncer de mama

Julia Camps Herrero
Hospital de la Ribera
Alzira

- Imagen RM multiparamétrica y radiomics
- Implicaciones fenotipos tumorales
  - imagen fenotipos tumorales
  - patrones de respuesta

Ann Surg Oncol (2015) 22:3184–3190
DOI 10.1245/s10434-015-4753-3

Annals of
SURGICAL ONCOLOGY
OFFICIAL JOURNAL OF THE SOCIETY OF SURGICAL ONCOLOGY

ORIGINAL ARTICLE – BREAST ONCOLOGY

Performance and Practice Guideline for the Use of Neoadjuvant Systemic Therapy in the Management of Breast Cancer

Dennis Holmes, MD[1], A. Colfry, MD[2], Brian Czerniecki, MD[3], Diana Dickson-Witmer, MD[4], C. Francisco Espinel, MD[5], Elizabeth Feldman, MD[6], Kristalyn Gallagher, DO[7], Rachel Greenup, MD[8], Virginia Herrmann, MD[9], Henry Kuerer, MD[10], Manmeet Malik, DO[11], Eric Manahan, MD[12], Jennifer O'Neill, MD[13], Mita Patel, MD[14], Molly Sebastian, MD[5], Amanda Wheeler, MD[15], and Rena Kass, MD[16]

Baseline Imaging	• Bilateral mammograms • Ipsilateral breast and axillary ultrasound • Contrast-enhanced MRI
Minimally Invasive Biopsies	• MIBB of breast and abnormal axillary node • Placement of tissue marker(s) at biopsy site(s) • Determination of tumor biomarkers (ER, PR, HER2/neu)
Consideration of NST	• Increase resectability of locally advanced breast cancer • Increase feasibility of BCS and cosmesis of Stage II & III breast cancer • Downstage axillary nodes
Systemic Staging	• Stage II: liver function studies & chest X-ray • Stage III: CT Chest abdomen +/- pelvis or PET/CT; bone scan or NaFl PET/CT • Symptom-guided imaging
Care Coordination	• Appropriate referrals to medical oncology, radiation oncology, plastic surgery, social work, etc. • Genetic counseling and testing, if indicated
Initiation of NST	• Neoadjuvant chemotherapy • Neoadjuvant endocrine therapy • Interval monitoring for tumor response, symptom management, compliance
Post-NST Imaging	• Ipsilateral mammograms • Ipsilateral breast and axillary ultrasound • Contrast-enhanced MRI
Decision for Surgery	• BCS vs. mastectomy with or without breast reconstruction • Sentinel node biopsy vs. axillary node dissection

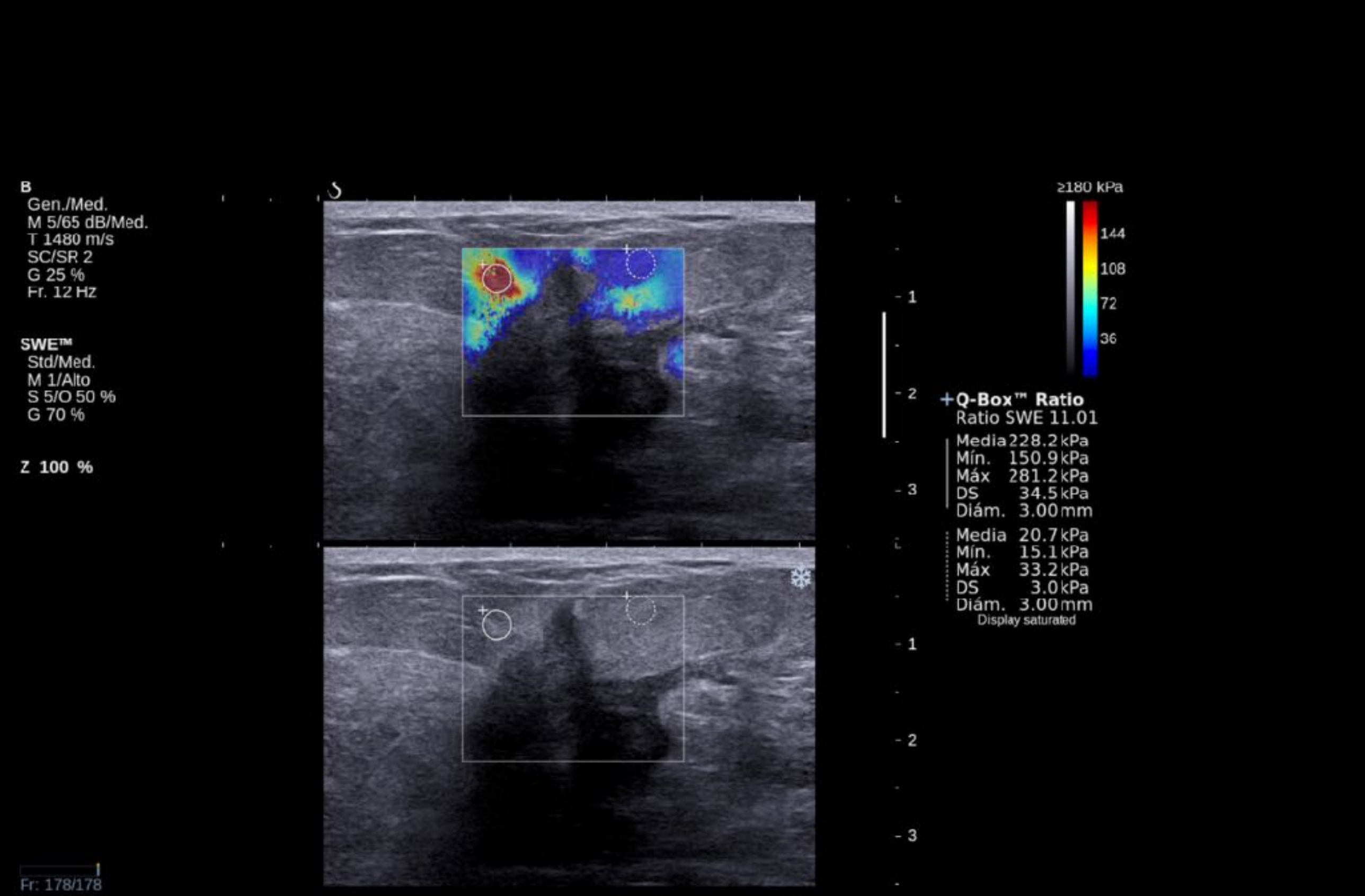
B
Gen./Med.
M 5/65 dB/Med.
T 1480 m/s
SC/SR 2
G 25 %
Fr. 12 Hz
SWE™
Std/Med.
M 1/Alto
S 5/O 50 %
G 70 %
Z 100 %
Fr: 178/178
≥180 kPa
144
108
72
36
Q-Box™ Ratio
Ratio SWE 11.01
Media 228.2 kPa
Mín. 150.9 kPa
Máx 281.2 kPa
DS 34.5 kPa
Diám. 3.00 mm
Media 20.7 kPa
Mín. 15.1 kPa
Máx 33.2 kPa
DS 3.0 kPa
Diám. 3.00 mm
Display saturated

La caverna de Platón

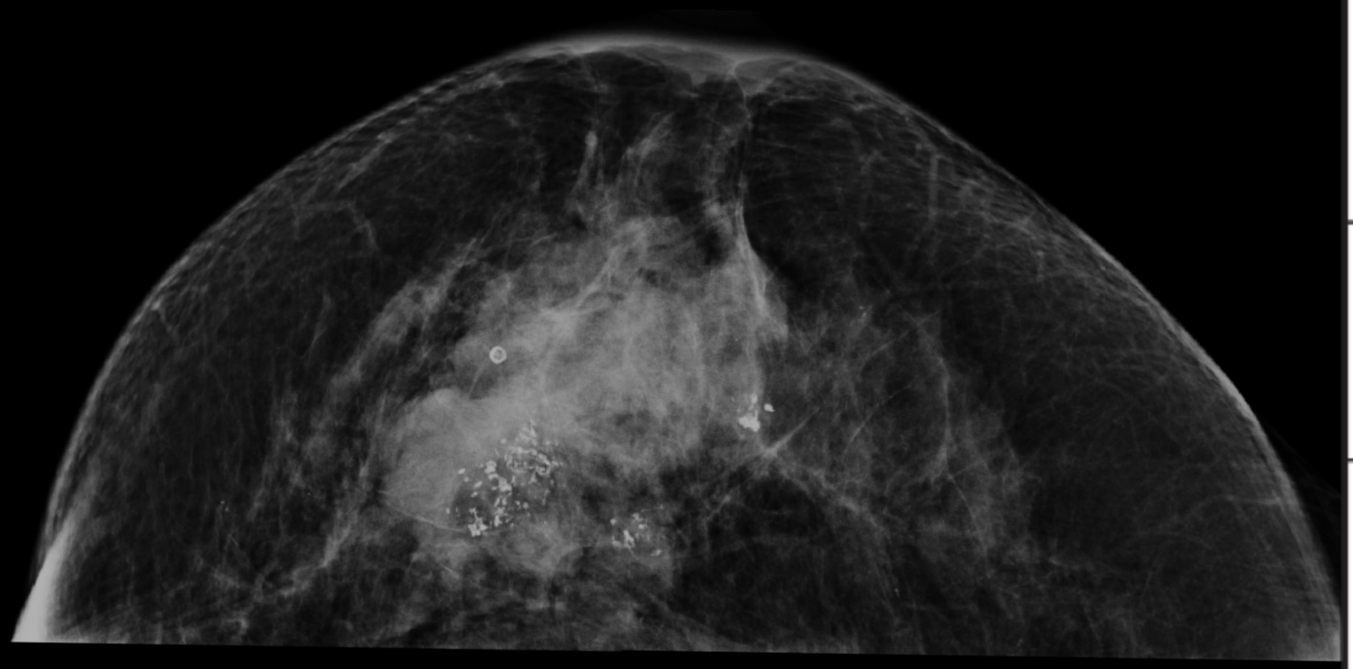

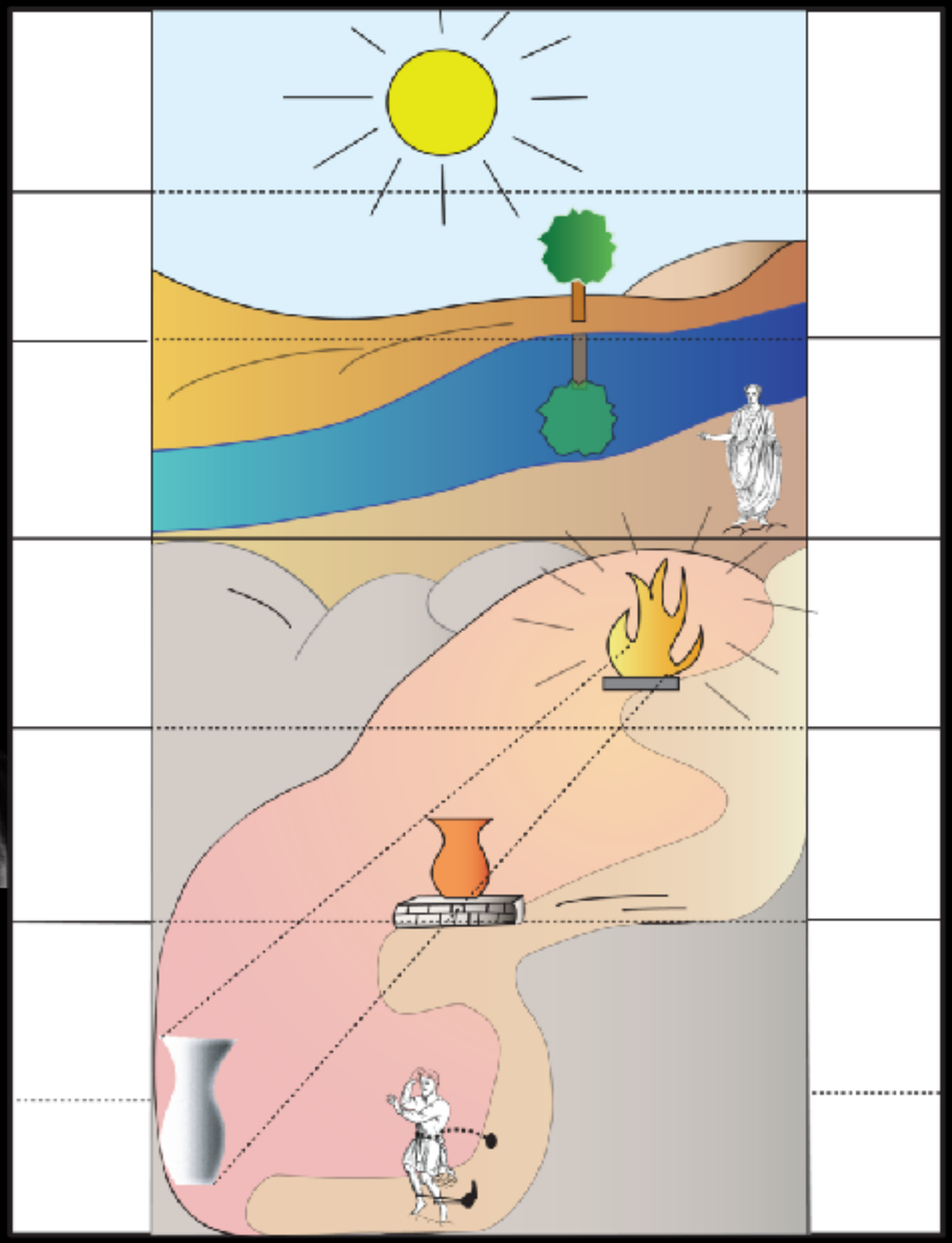

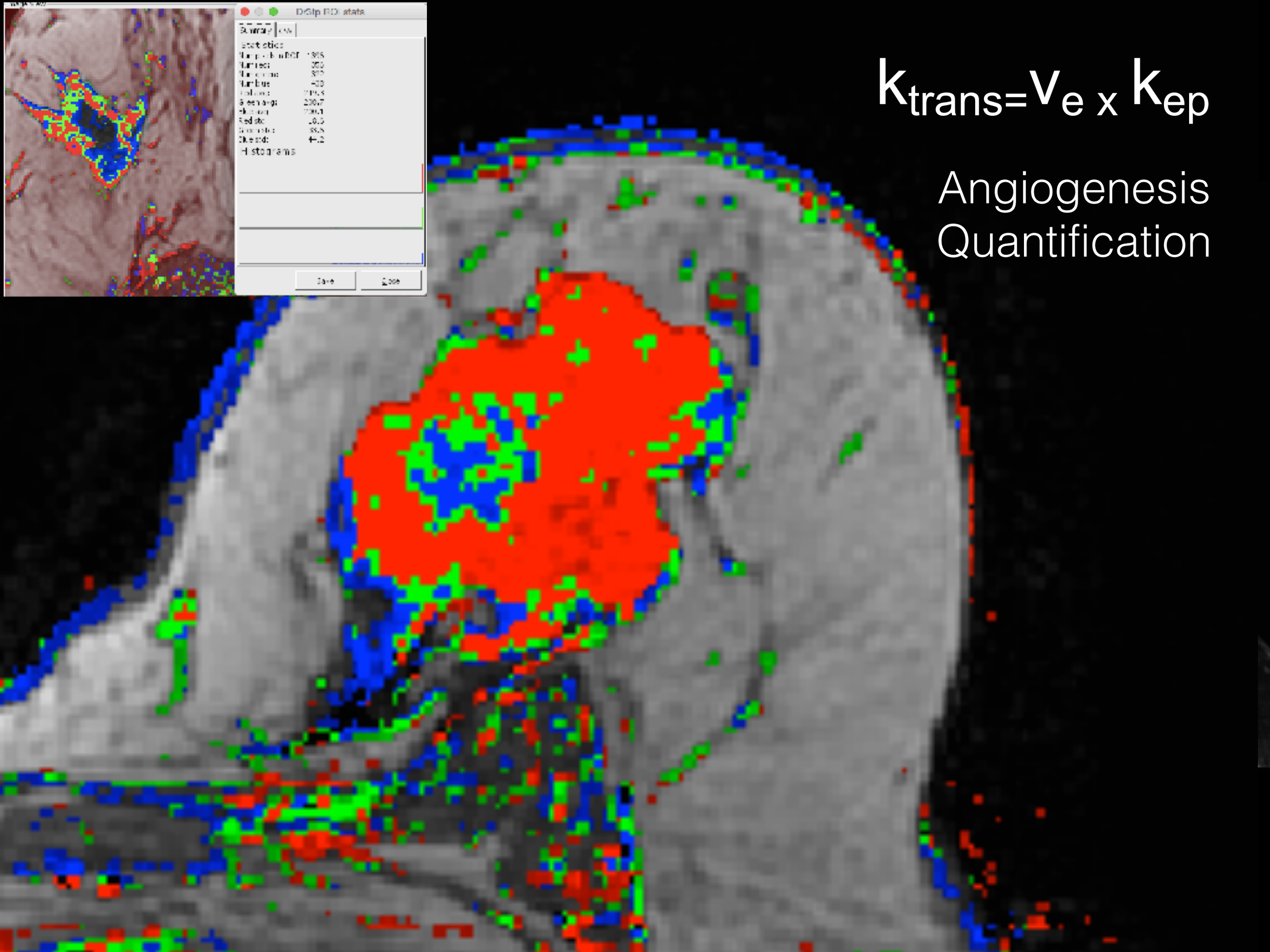
$k_{trans}=v_e \times k_{ep}$
Angiogenesis
Quantification

Serial Measures “in vivo”

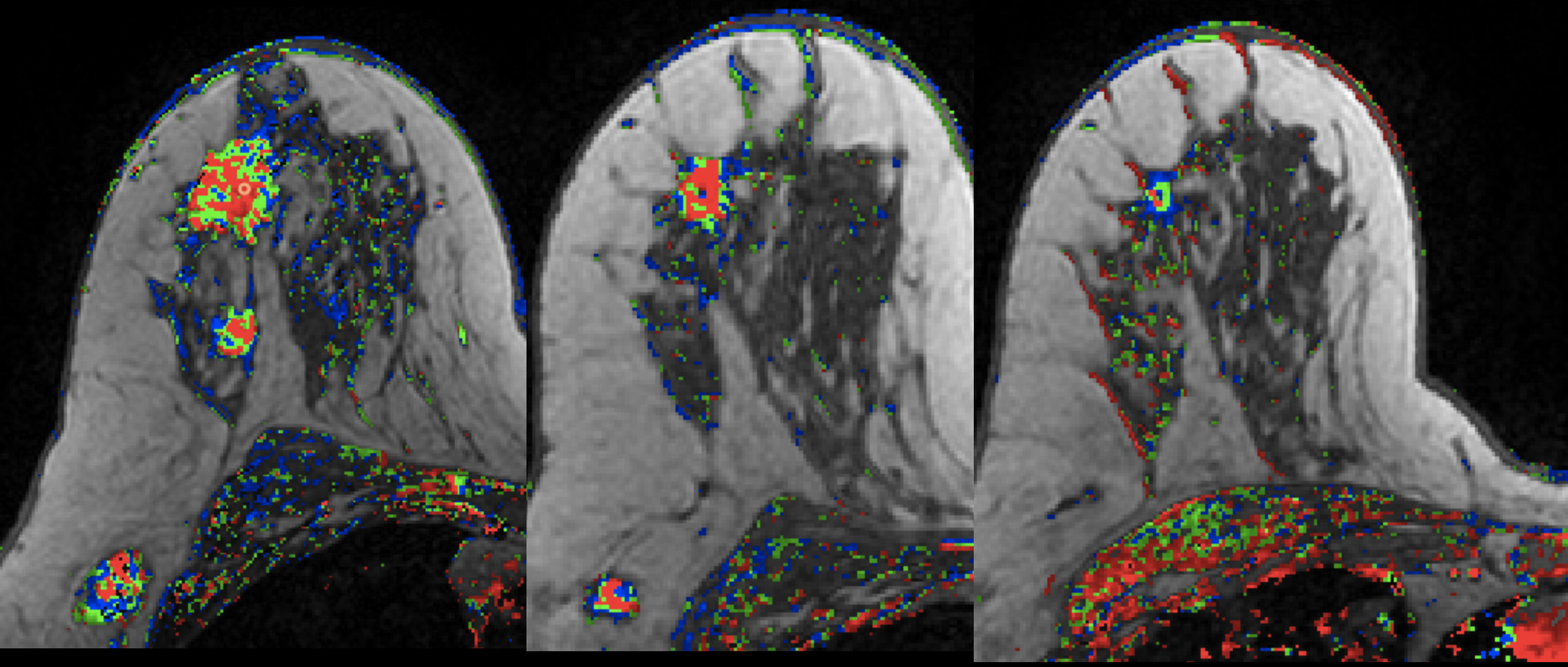

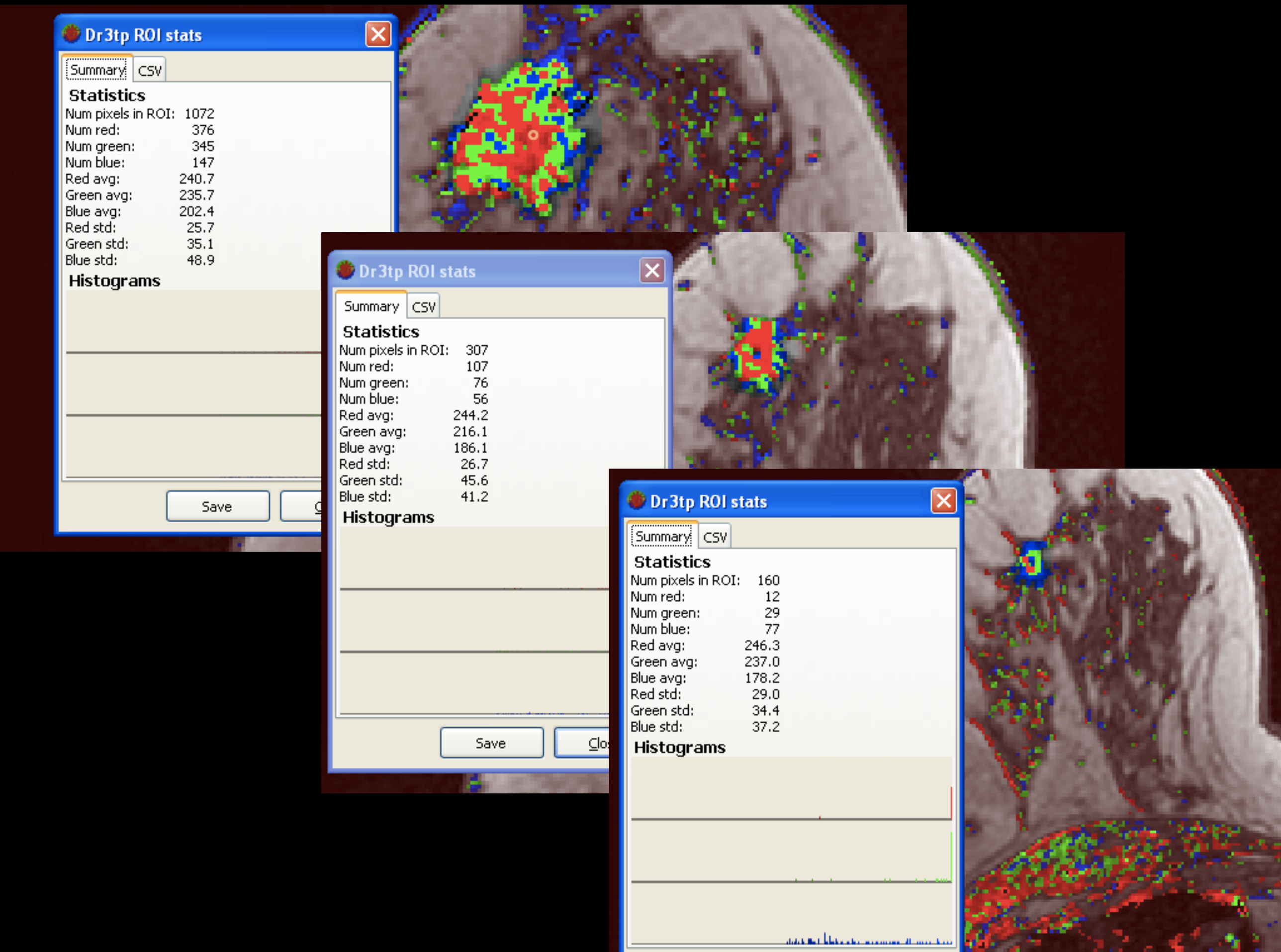
Dr3tp ROI stats
Summary
CSV
Statistics
Num pixels in ROI: 1072
Num red: 376
Num green: 345
Num blue: 147
Red avg: 240.7
Green avg: 235.7
Blue avg: 202.4
Red std: 25.7
Green std: 35.1
Blue std: 48.9
Histograms
Save
Dr3tp ROI stats
Summary
CSV
Statistics
Num pixels in ROI: 307
Num red: 107
Num green: 76
Num blue: 56
Red avg: 244.2
Green avg: 216.1
Blue avg: 186.1
Red std: 26.7
Green std: 45.6
Blue std: 41.2
Histograms
Save
Dr3tp ROI stats
Summary
CSV
Statistics
Num pixels in ROI: 160
Num red: 12
Num green: 29
Num blue: 77
Red avg: 246.3
Green avg: 237.0
Blue avg: 178.2
Red std: 29.0
Green std: 34.4
Blue std: 37.2
Histograms

DTI
Quantification of restricted movement of water molecules
Tissue Architecture

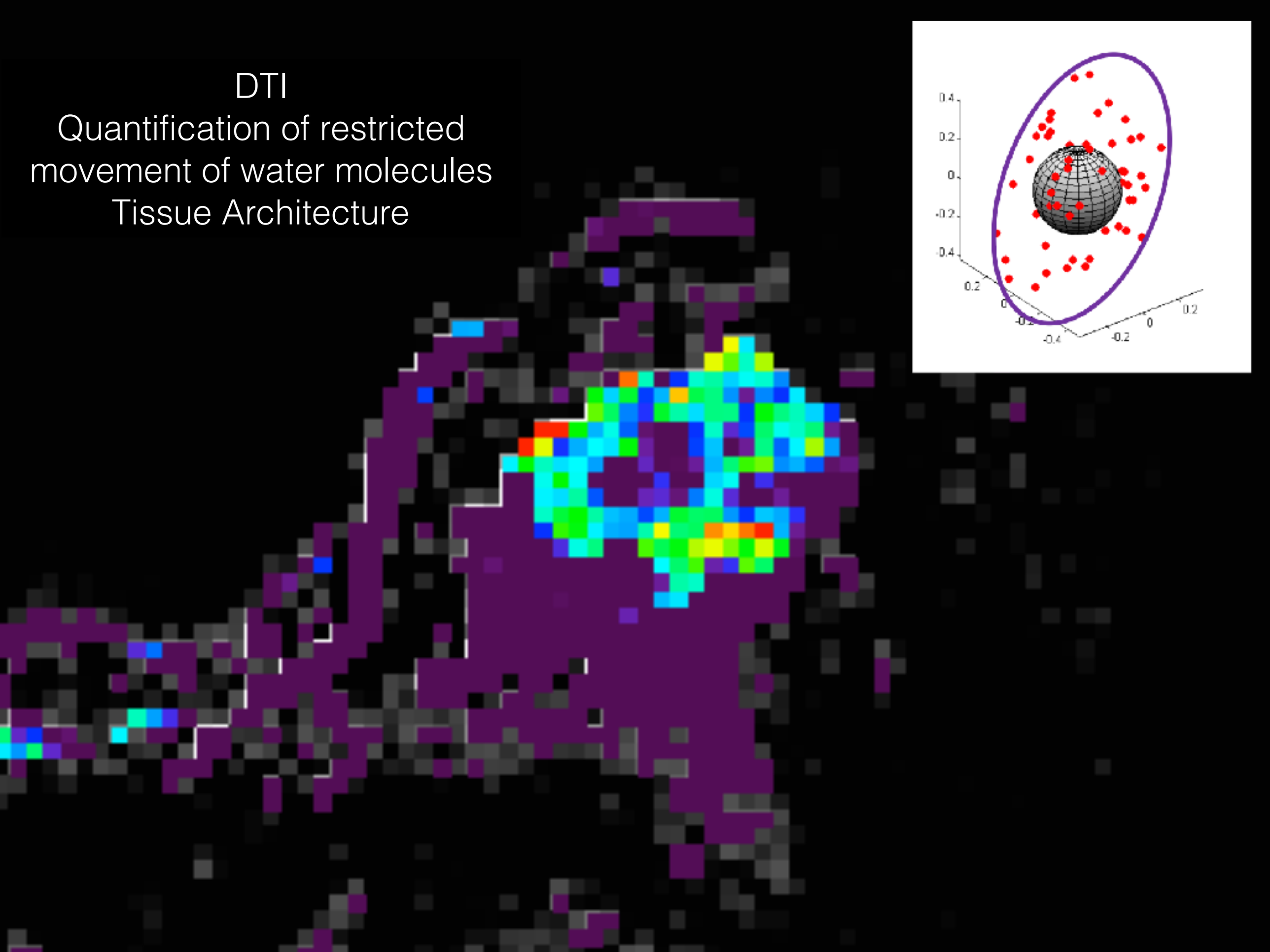

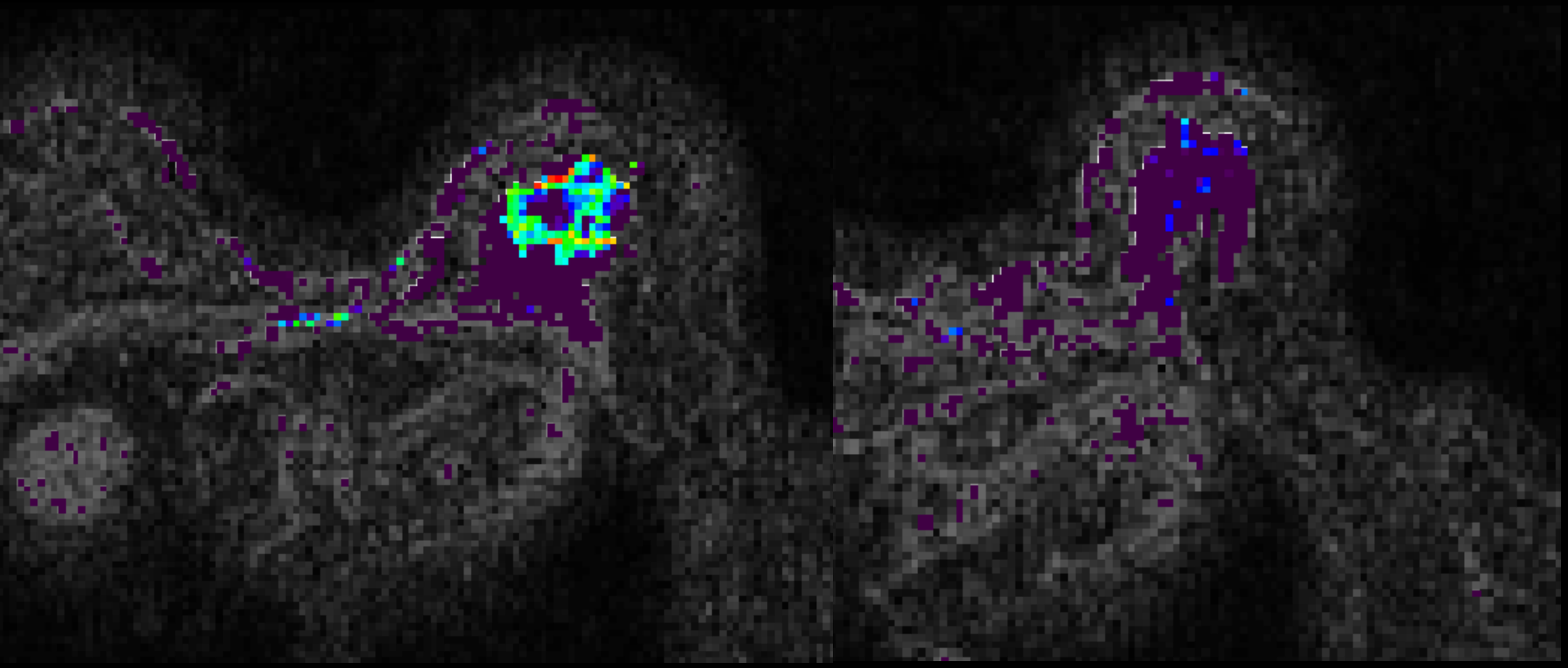

Respuesta Completa
Estudio Precoz tras C2 Antraciclinas SIN CONTRASTE
Apoptosis, integridad de membranas celulares

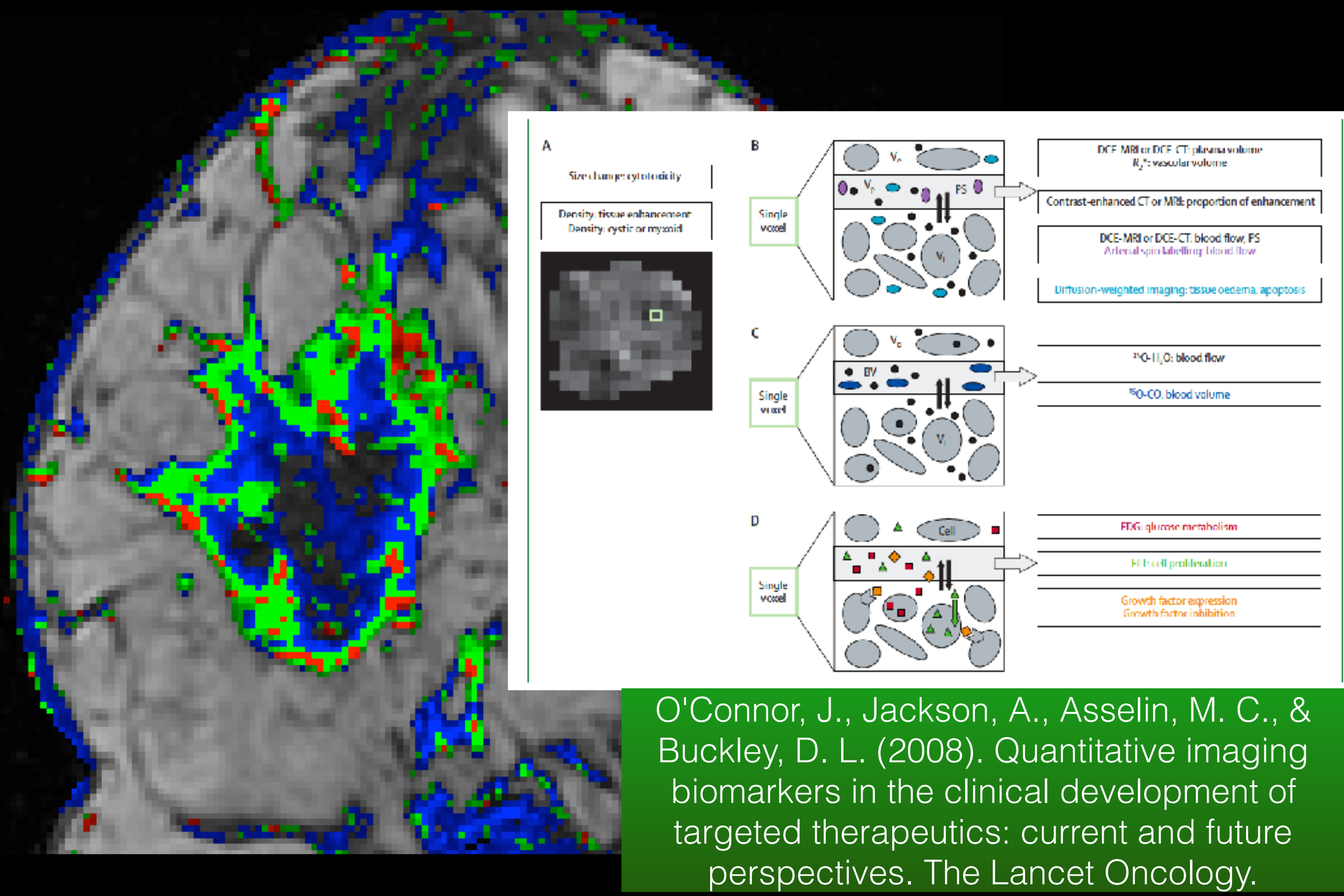

O'Connor, J., Jackson, A., Asselin, M. C., & Buckley, D. L. (2008). Quantitative imaging biomarkers in the clinical development of targeted therapeutics: current and future perspectives. The Lancet Oncology.

in-plane resolution = 0,7 mm

RM Multiparamétrica como BM de imagen

- El abordaje multiparamético (MP) incorpora parámetros funcionales
  - RM+Contraste -> permeabilidad vascular neovasos
  - RM difusión -> celularidad e integridad membranas celulares
  - RM espectroscopia -> composición química

Rahbar, H., & Partridge, S. C. (2016). Multiparametric MR Imaging of Breast Cancer. Magnetic Resonance Imaging Clinics of North America, 24(1), 223–238.

La imagen multiparamétrica de la RM es más que la suma de las distintas secuencias funcionales de RM, permite una mejor comprensión de los procesos biológicos y la respuesta al tratamiento mediante los BIOMARCADORES DE IMAGEN

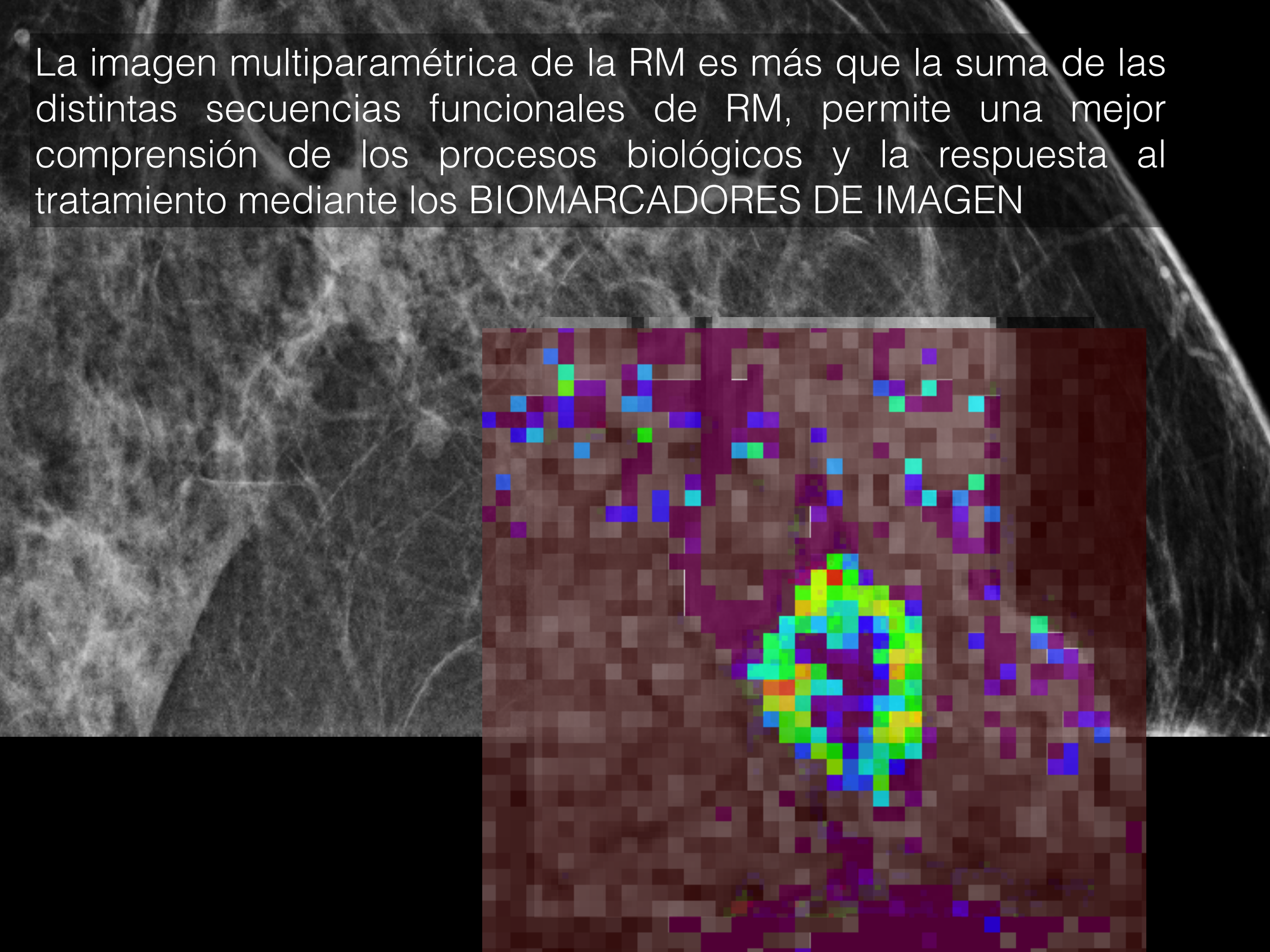

What is Radiogenomics/Radiomics?

- Radiogenomics is the correlation between imaging features (phenotypic disease manifestations) and cancer gene expression (genotypic information).

- Radiomics refers to the high throughput extraction and analysis of large amounts of features from images to build descriptive and predictive models relating image features to phenotypes or gene–protein signatures

Kumar, et al., J MRI, 2012

Radiomics to predict Chemotherapy Response

Timepoints 1 and 2 with associated parametric features are co-registered and the features are extracted.

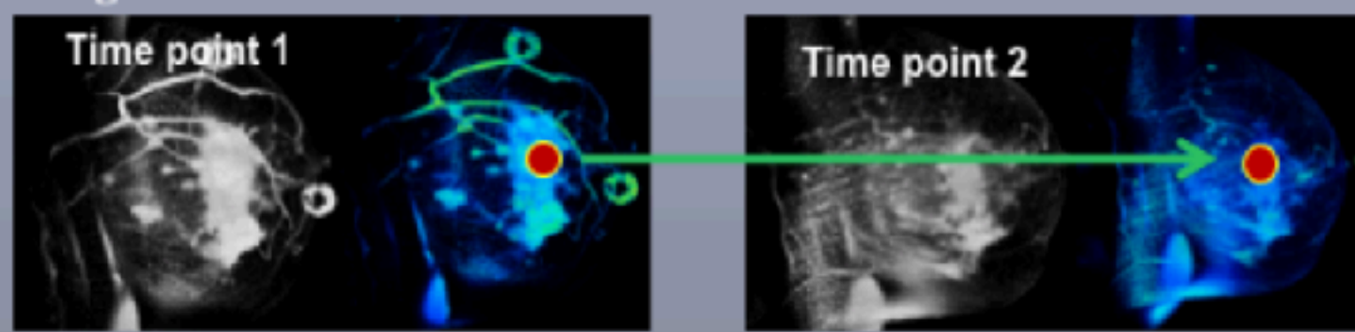

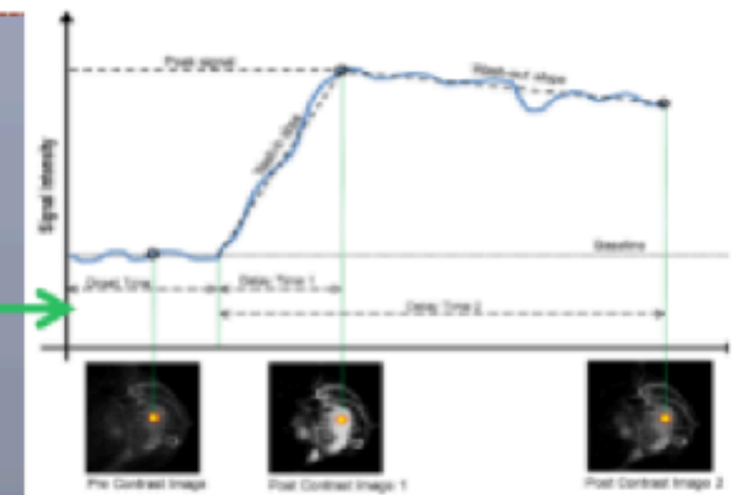

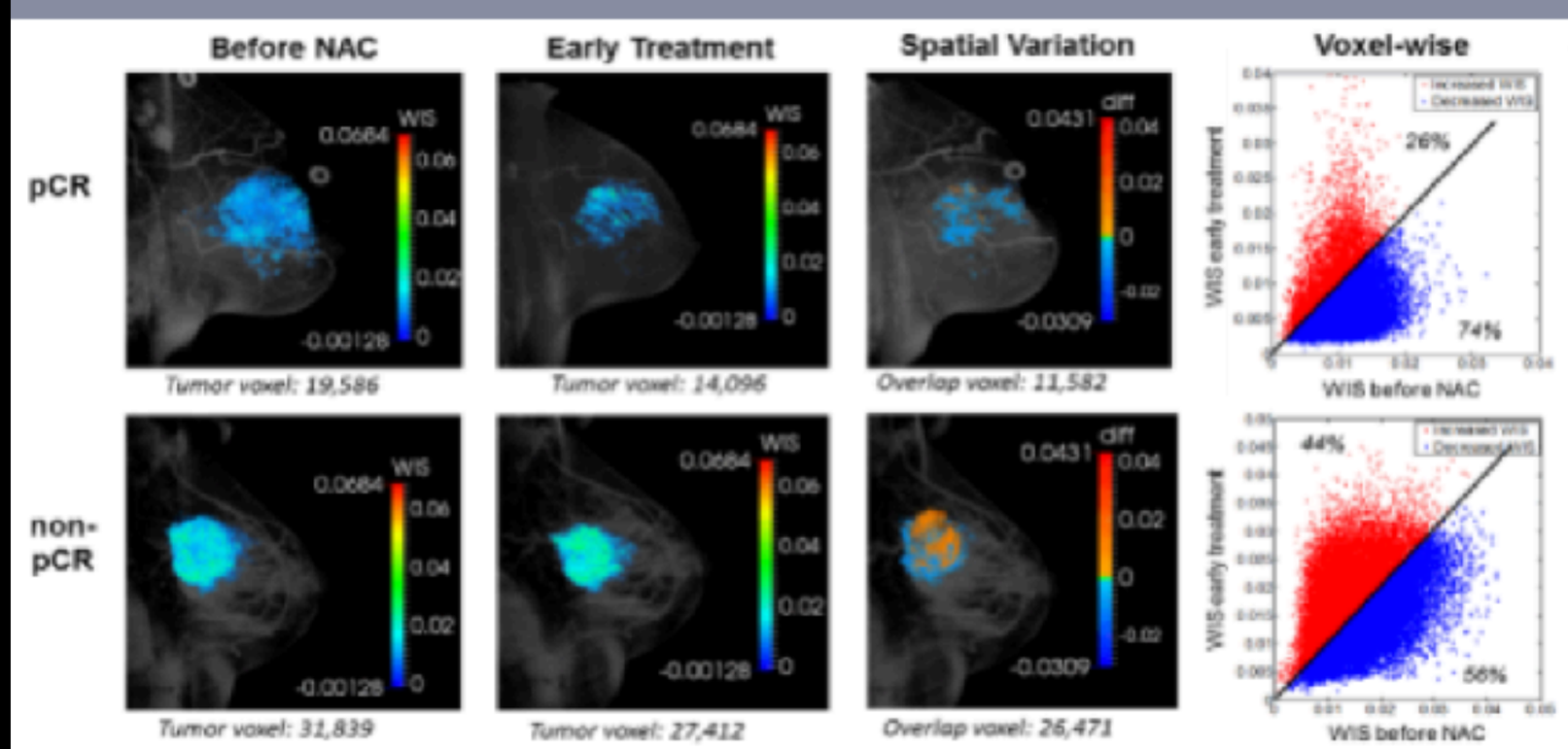

Extracted features such as wash-in-slope (WIS) are analyzed across time to construct models of response.

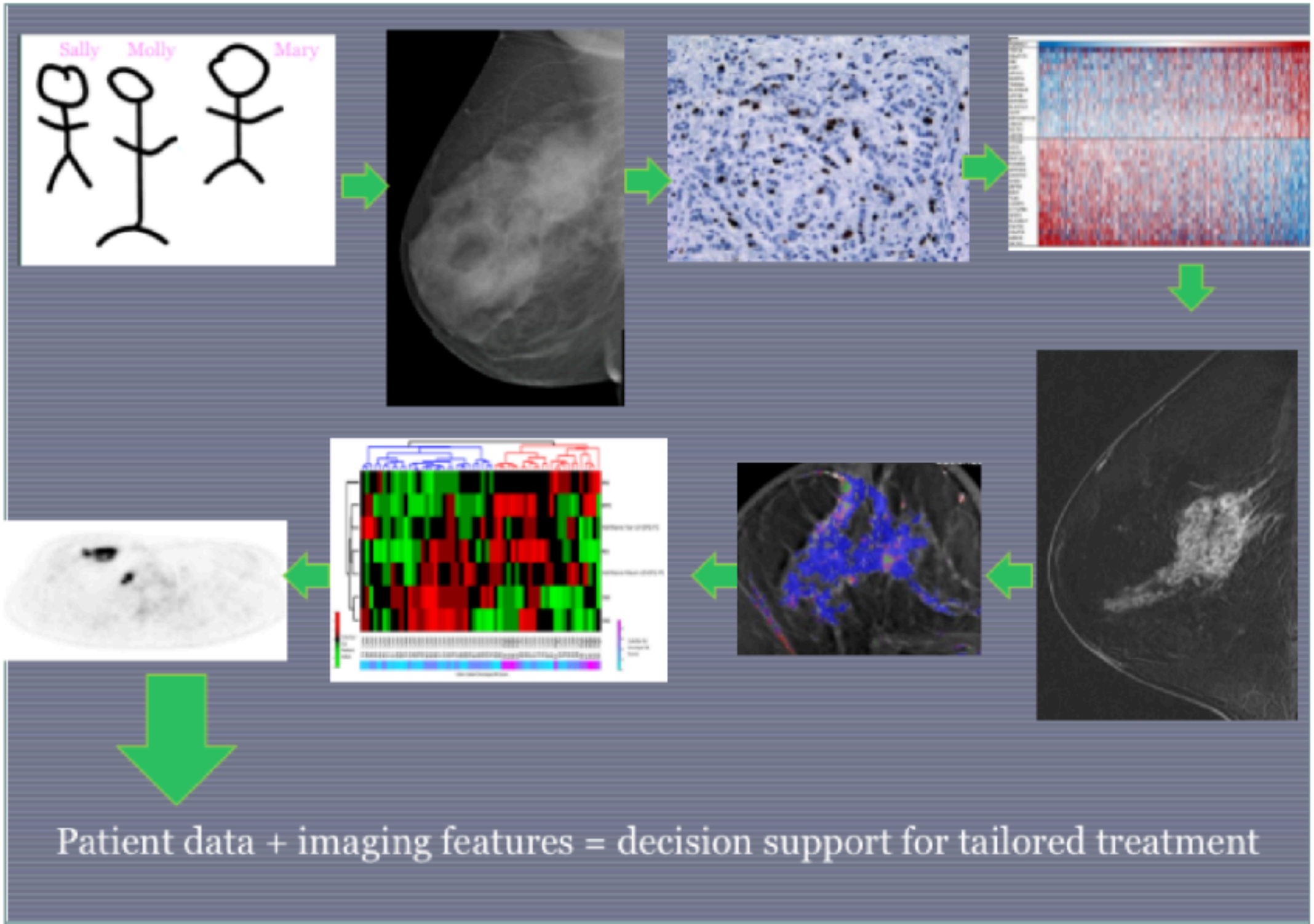

McDonald, et al., J Nuc. Med, 2016; Mahrooghy , Ashraf , Daye, McDonald et al., IEEE TBME 2015

Yuan 2010	Sensitivity for pCR 0.63 Specificity for residual tumor 0.91
Marinovich 2012 Systematic Review	13 studies. *PK models and volume better than time-intensity curves and diameter*
Prevos 2012 Systematic Review	15 studies. Pre-treatment predictors of response. *Tumor diameter/ volume, PK parameters, ADC: evidence is weak and based on underpowered study results and heterogeneous study results designs*
Marinovich 2013 Meta-analysis	44 studies. Sensitivity (residual tumor) Specificity (pCR) *Accuracy was lower when pCR was more rigorously defined, and specificity was lower when test negativity thresholds were more stringent; these definitions require standardization. Overall AUC for MRI 0.88*
Lobbes 2013 Systematic Review	35 studies. Ability to predict pCR. *Correlation coefficients of residual tumor size (MRI-pathology) were good (0,69). Over and underestimation and affected by treatment regimen and BC subtype*
Wu 2012 Meta-analysis DCE and DWI	34 studies. DW-MRI more sensitive (0.93) and DCE-MR more specific (0.91). Combined use has the potential to improve diagnostic performance

Resumen de la Evidencia

- RM superior a las técnicas convencionales (mamografía/eco)
- RM predice mejor la respuesta parcial o NR que la pRC
- La definición de pRC (CDIS), el sub-tipo tumoral y el tratamiento influyen
- RM-difusión predice respuesta ANTES que la RM+C (Pickles 2006, Sharma 2009)
- RM-difusión sens/esp 0.93/0.82
- RM+C sens/esp 0.68/0.91

CDIS residual

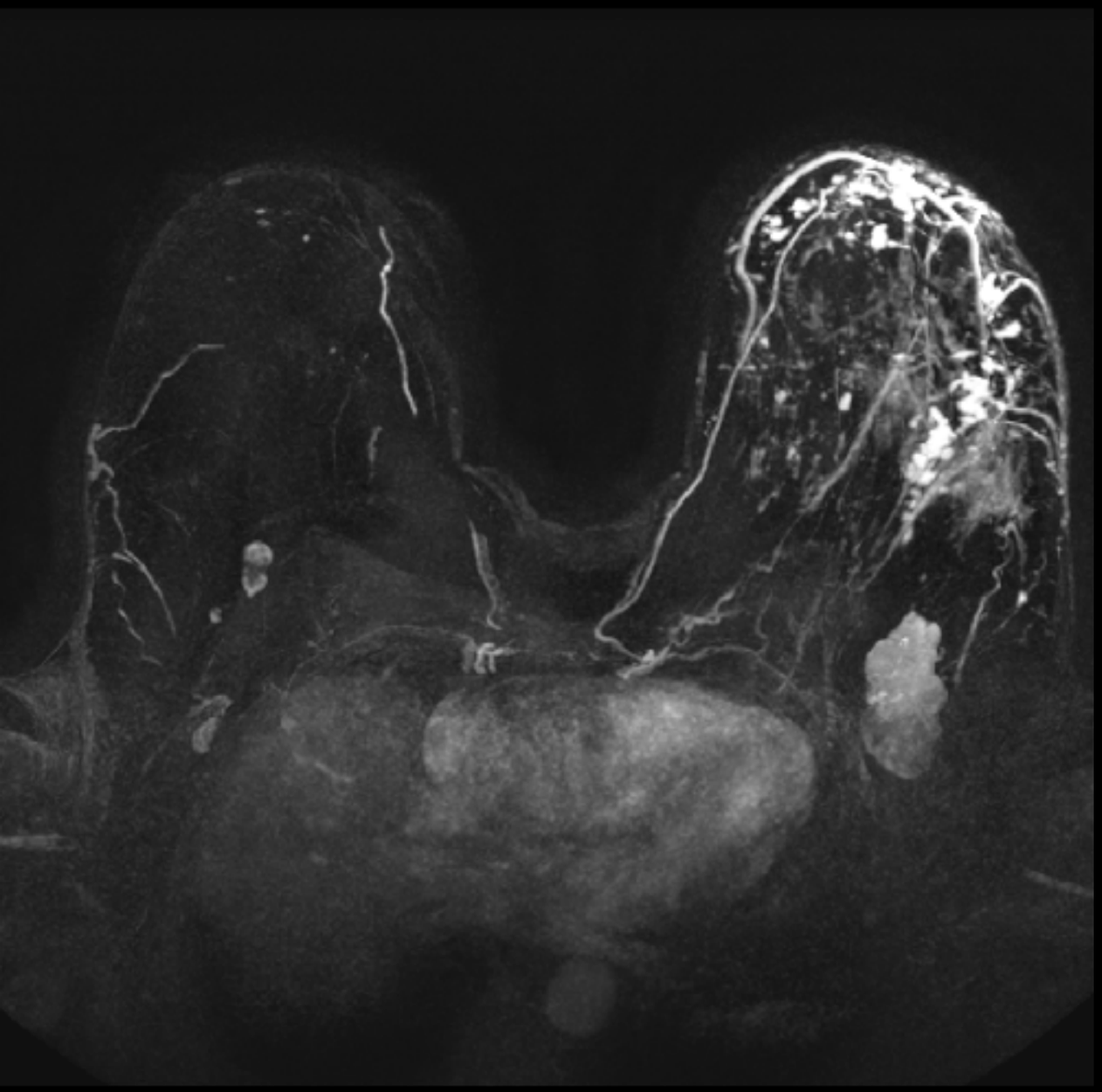

RESIDUAL DCIS

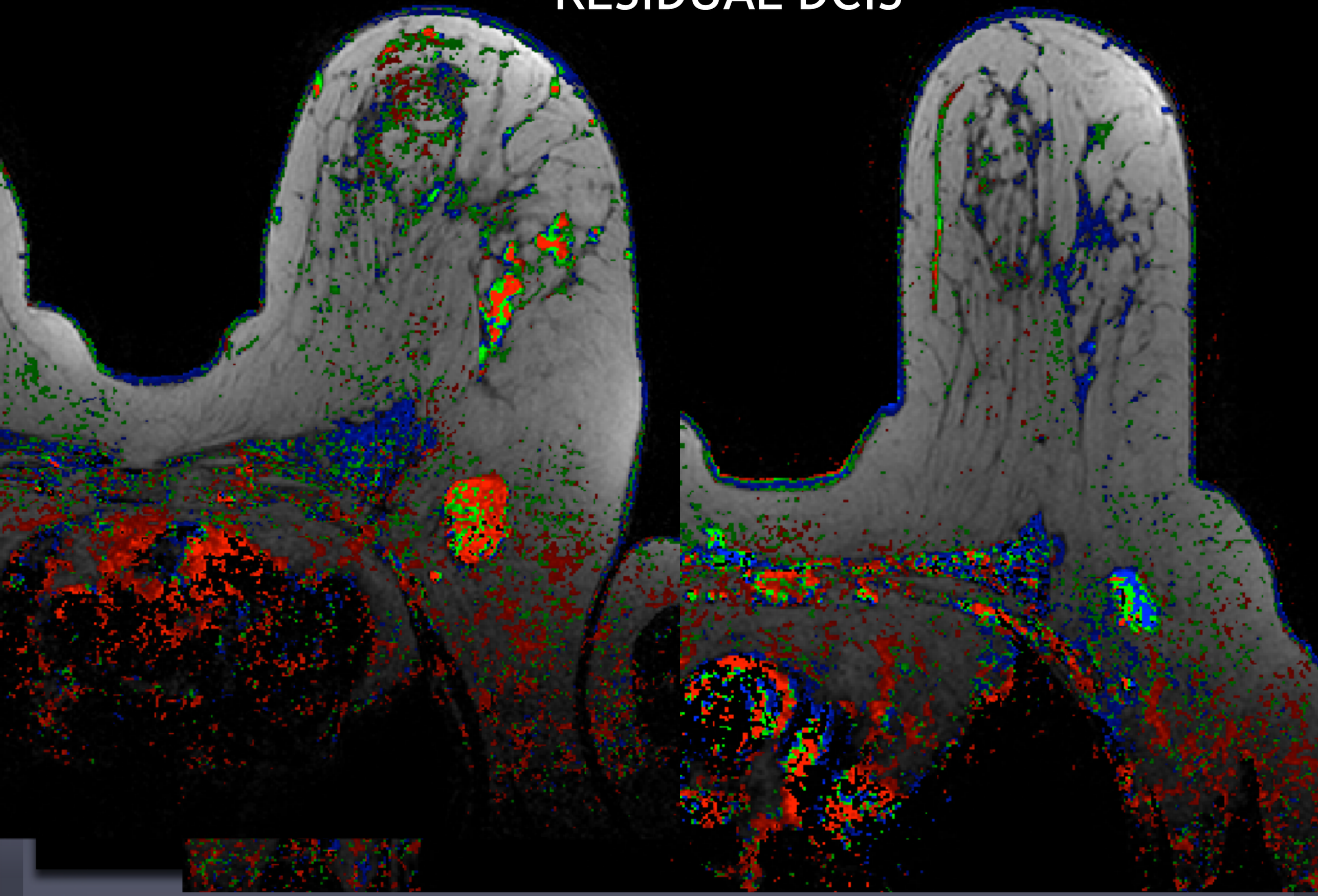

Morphologic Response Patterns

Concentric Response

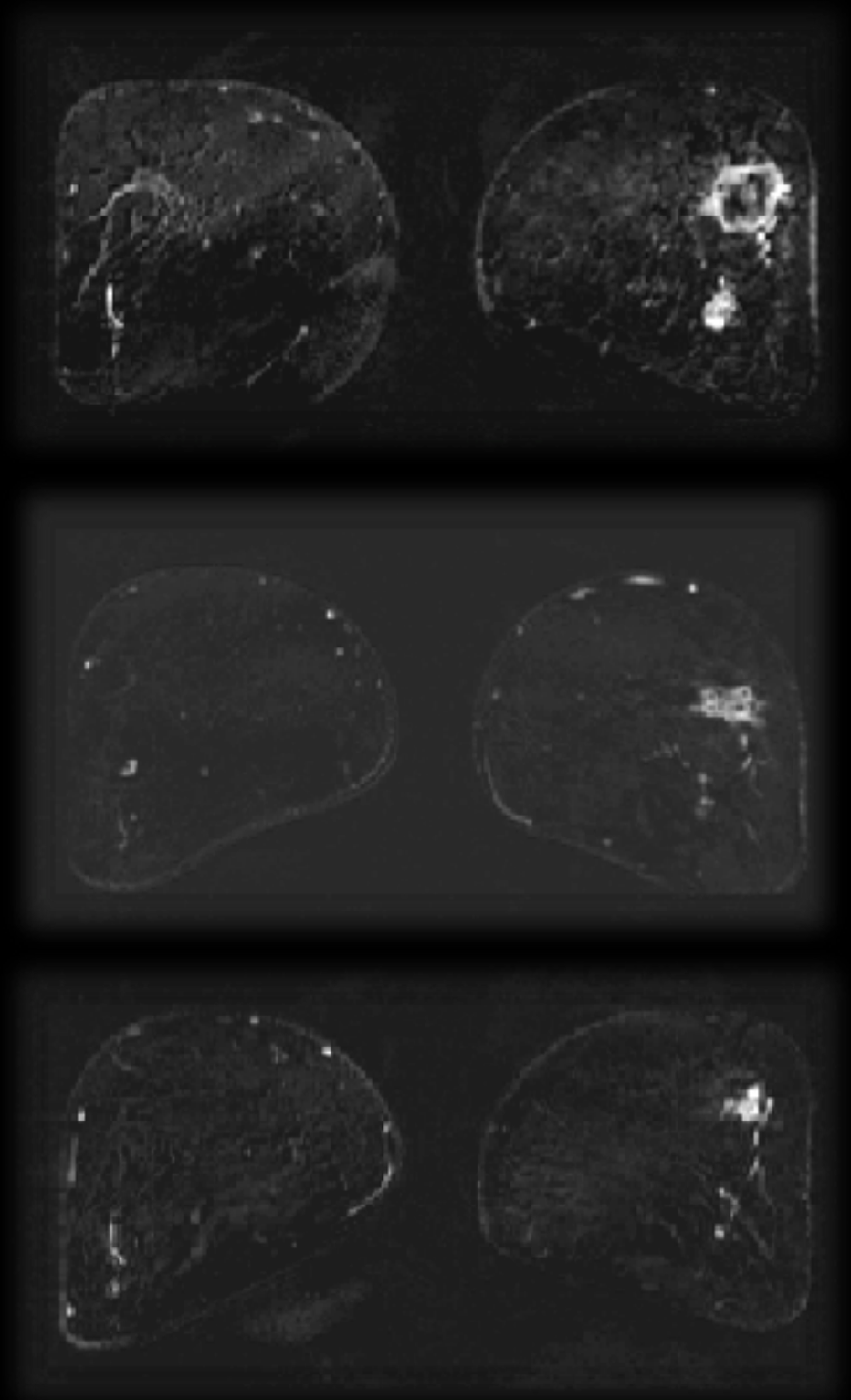

Fragmented Response

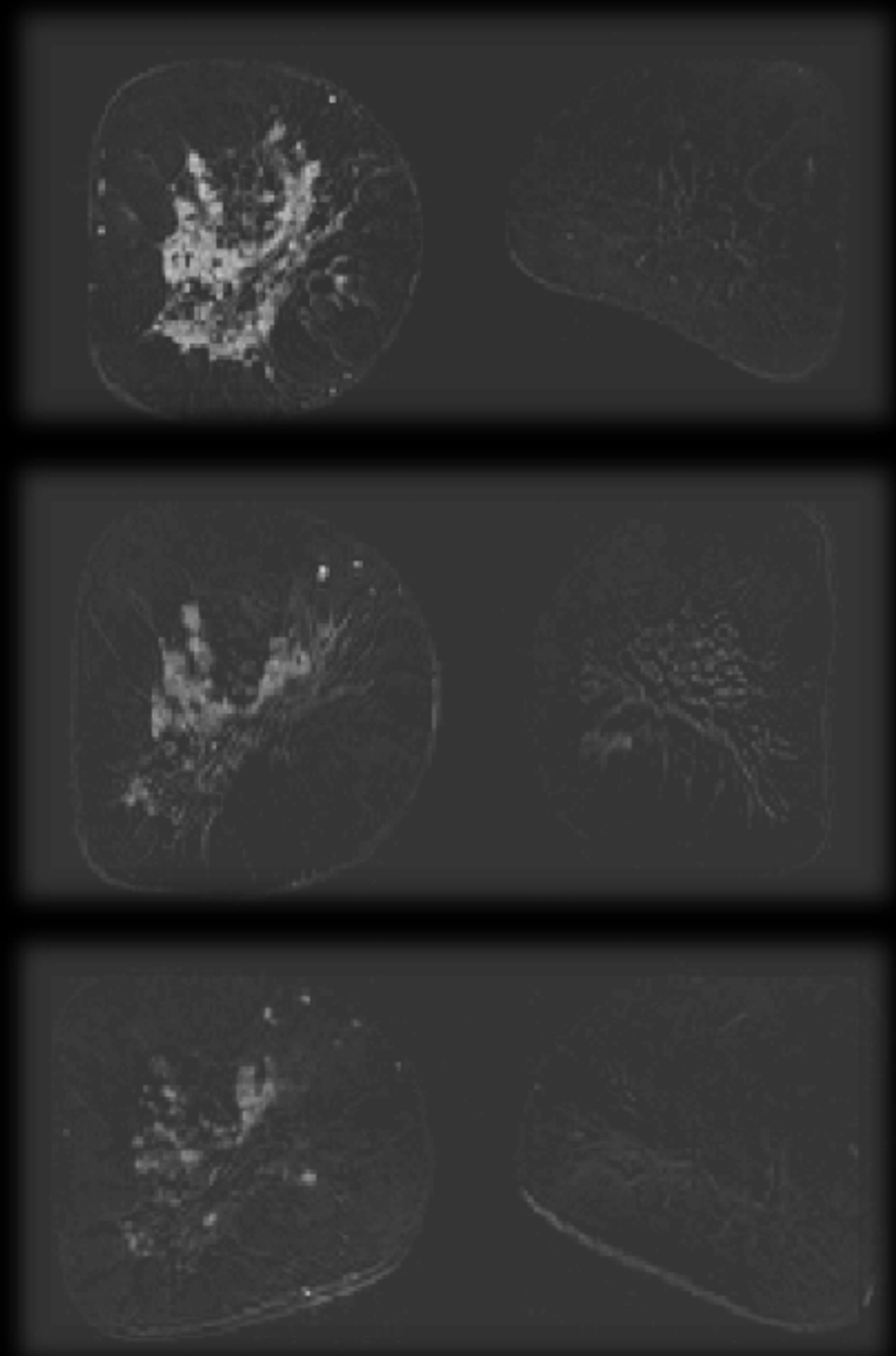

	Luminal A	BASAL HER 2+
Path Response	+	+++
MR response pattern	Fragmented	Concentric
Rad-path correlation	FP (fibrosis and duct ectasia) +	+++
Diagnostic Accuracy	50%	70-80%

55 pacientes - Luminal

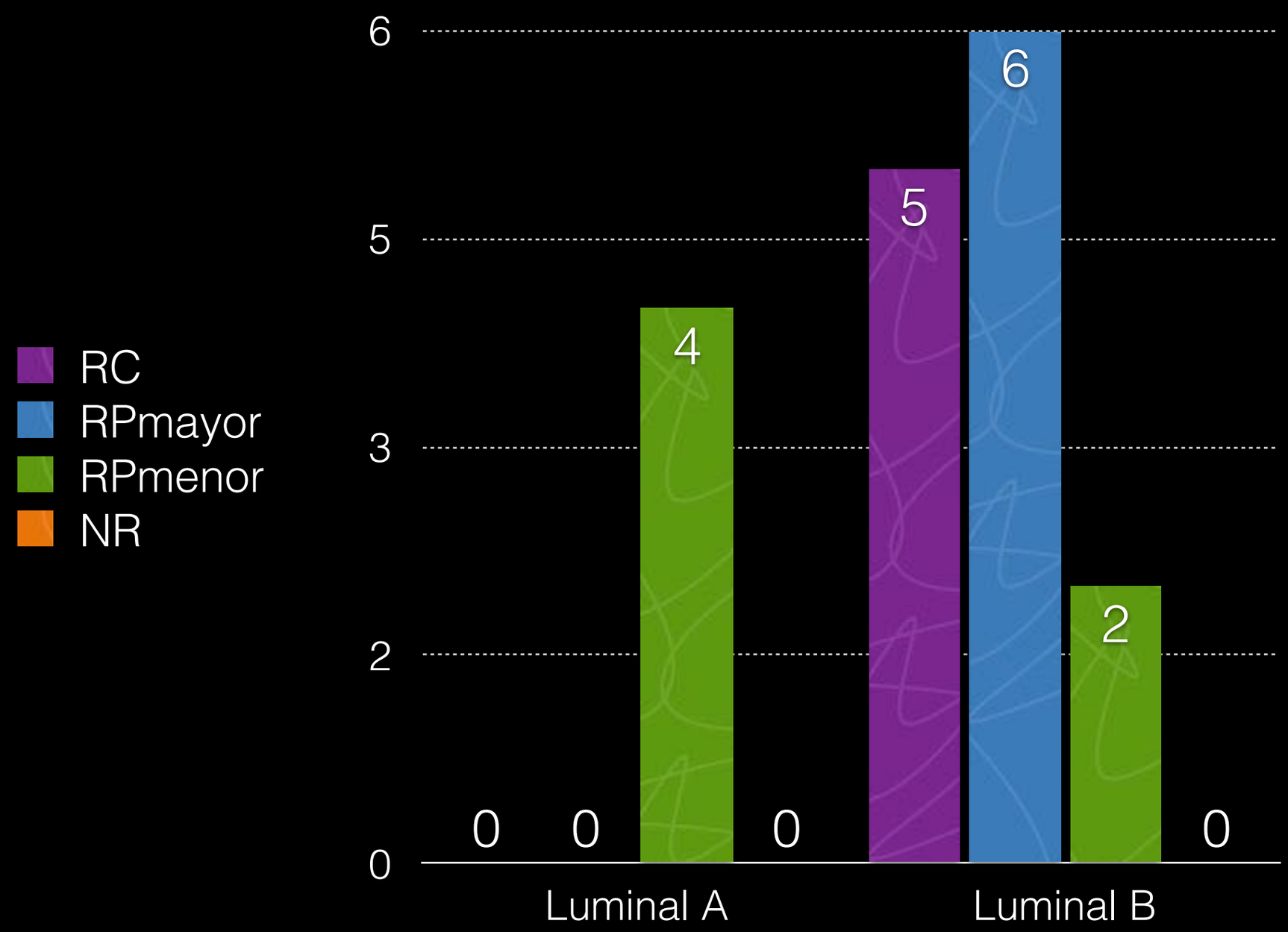

4 pacientes 13 pacientes

55 pacientes - HER2 y TN

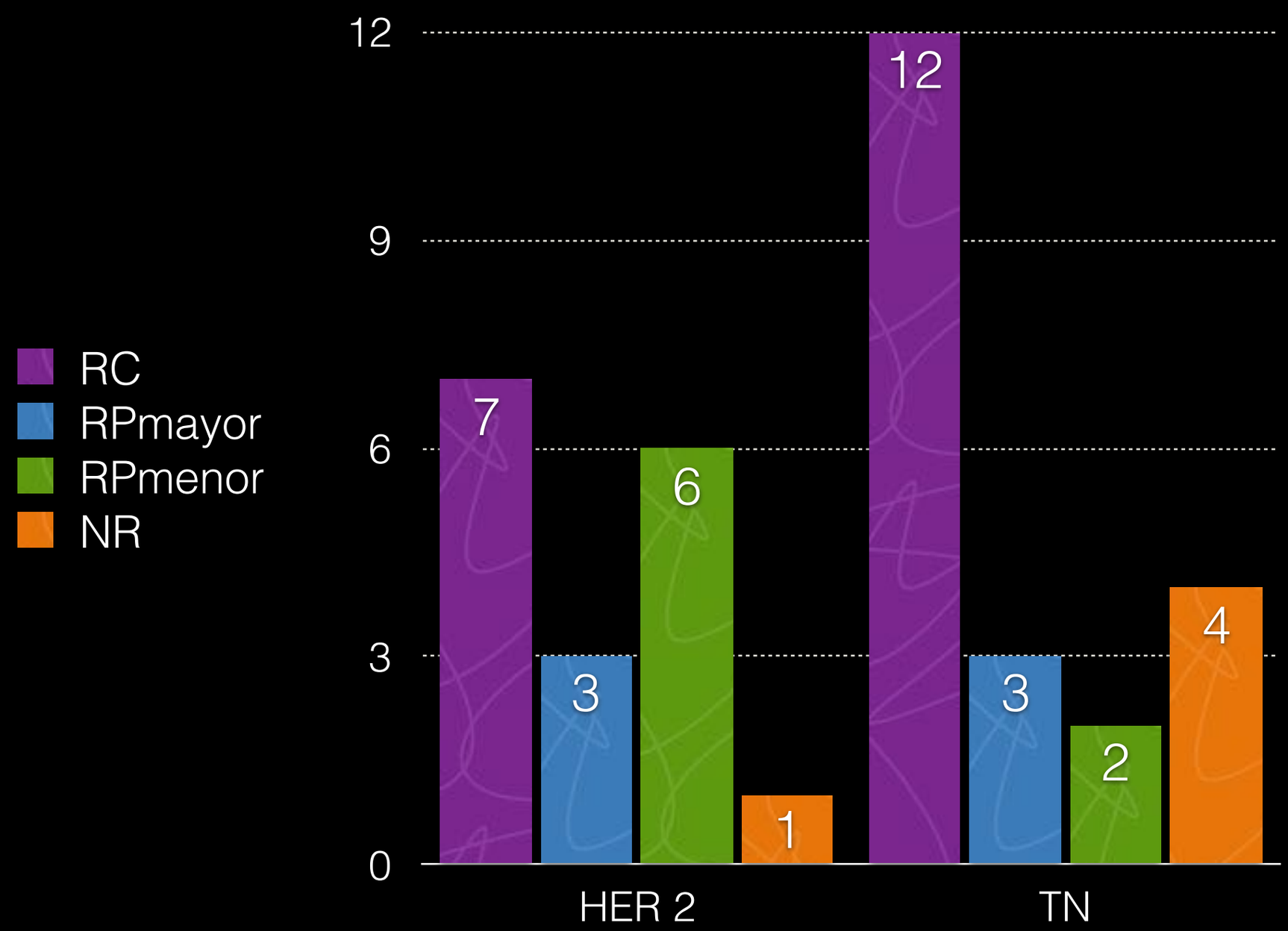

17 pacientes 21 pacientes

Subtipo Luminal

- Reacción desmoplásica, espículas
- Halo hiperecogénico y mala transmisión acústica
- Captación heterogénea
- RM predice peor la respuesta a la neoadyuvancia, especialmente si respuesta fragmentada

Luminal A

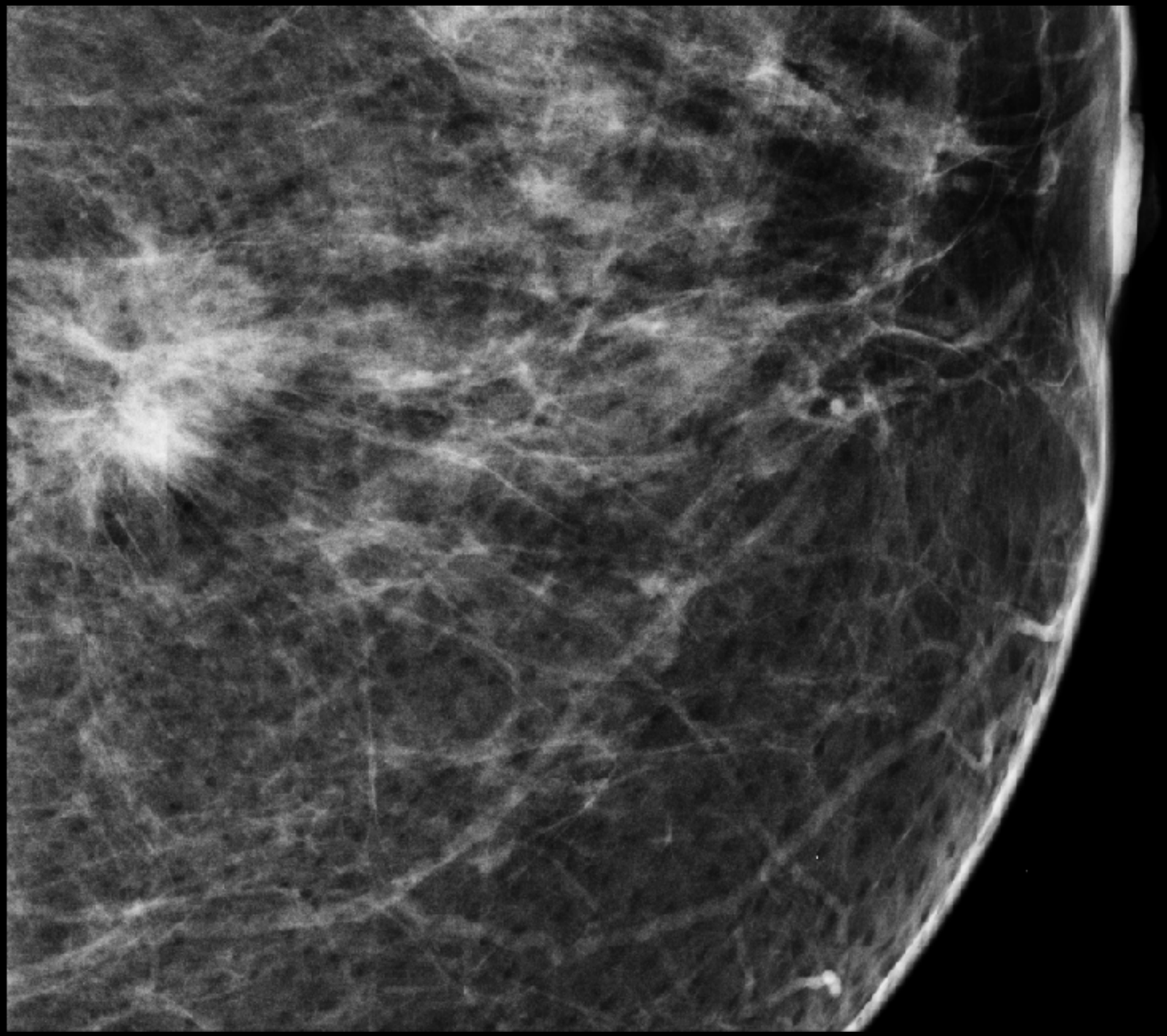

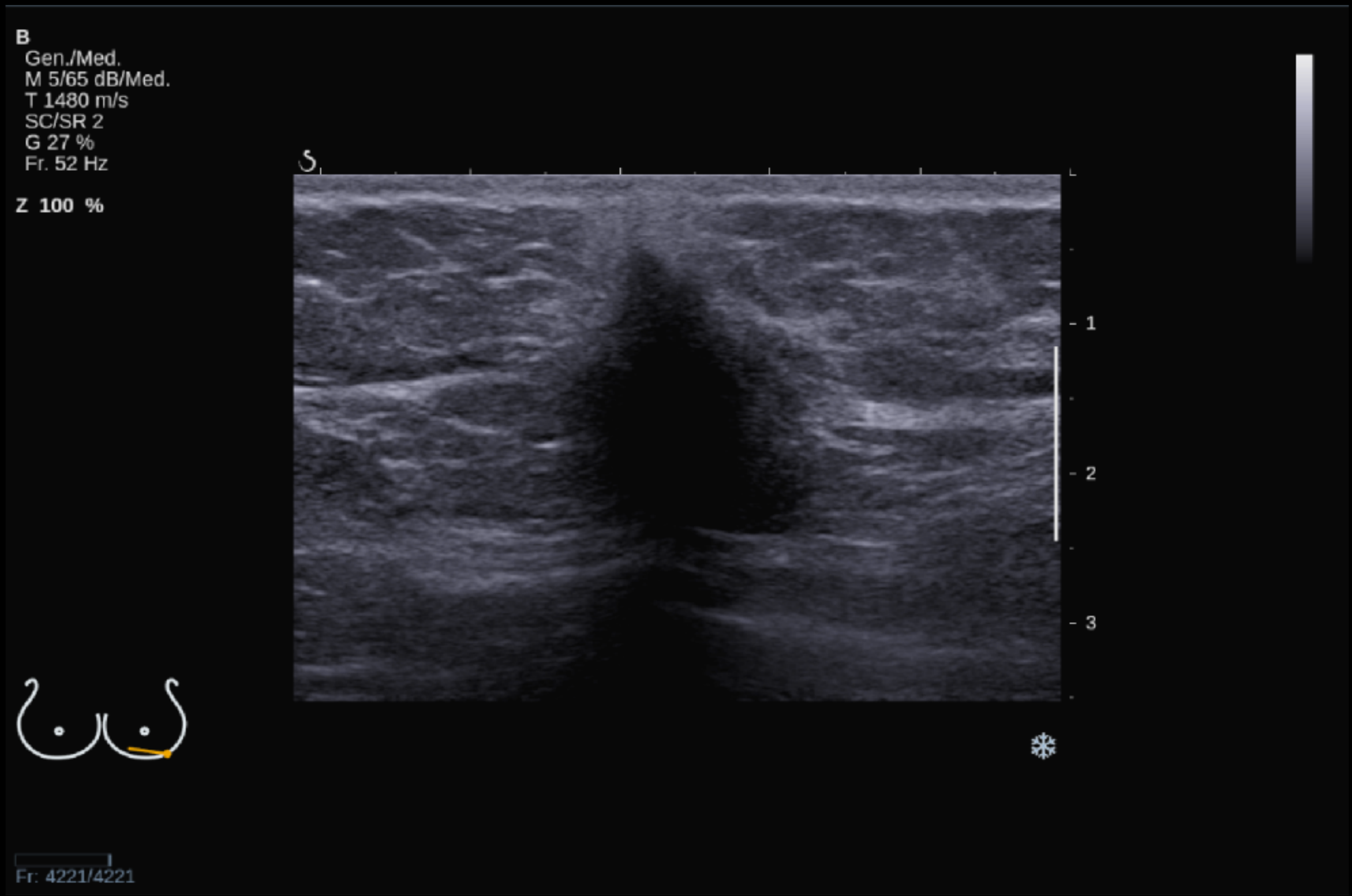
B
Gen./Med.
M 5/65 dB/Med.
T 1480 m/s
SC/SR 2
G 27 %
Fr. 52 Hz
Z 100 %
1
2
3
Fr: 4221/4221


T2 Espículas

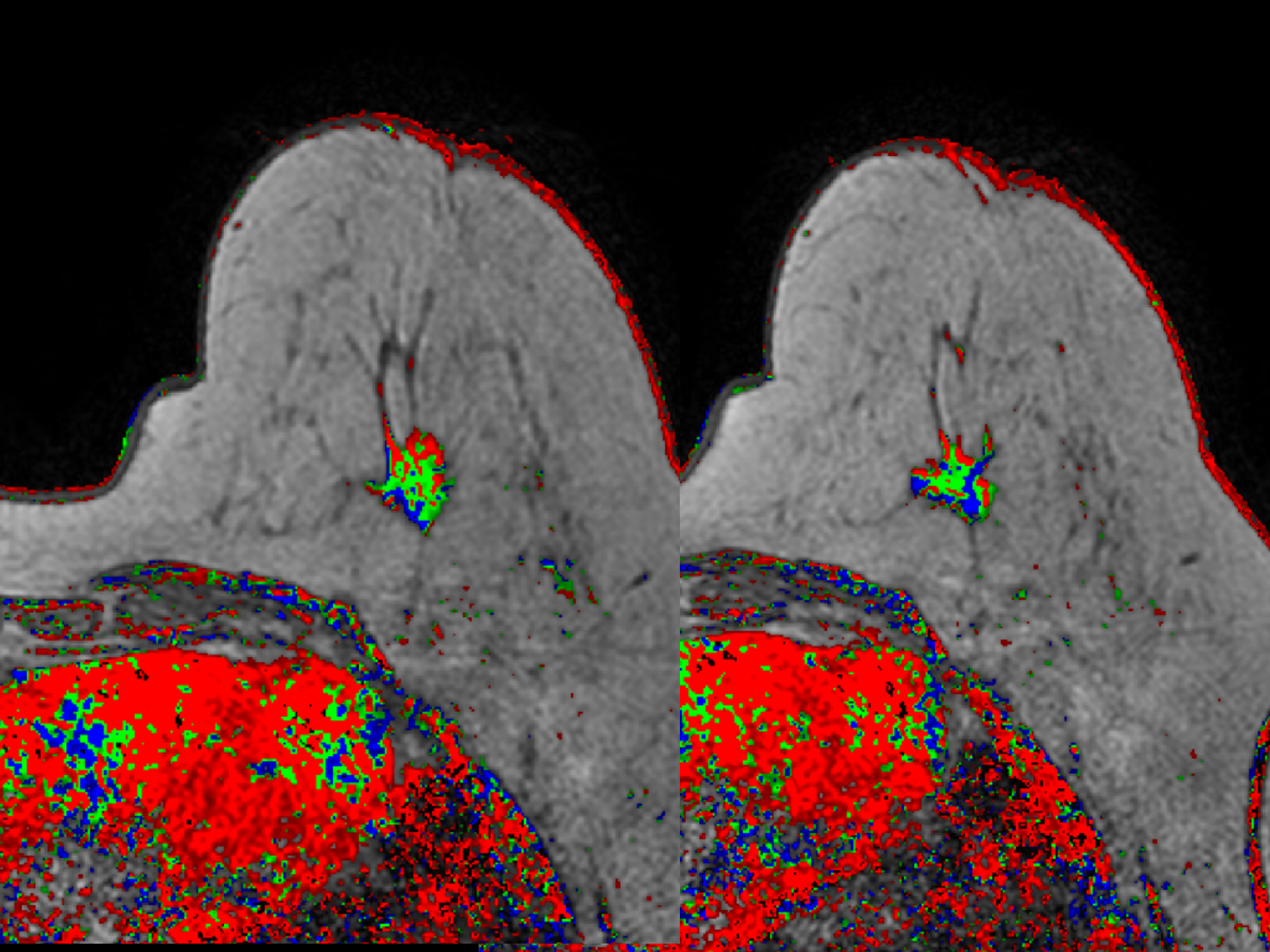

Luminal B

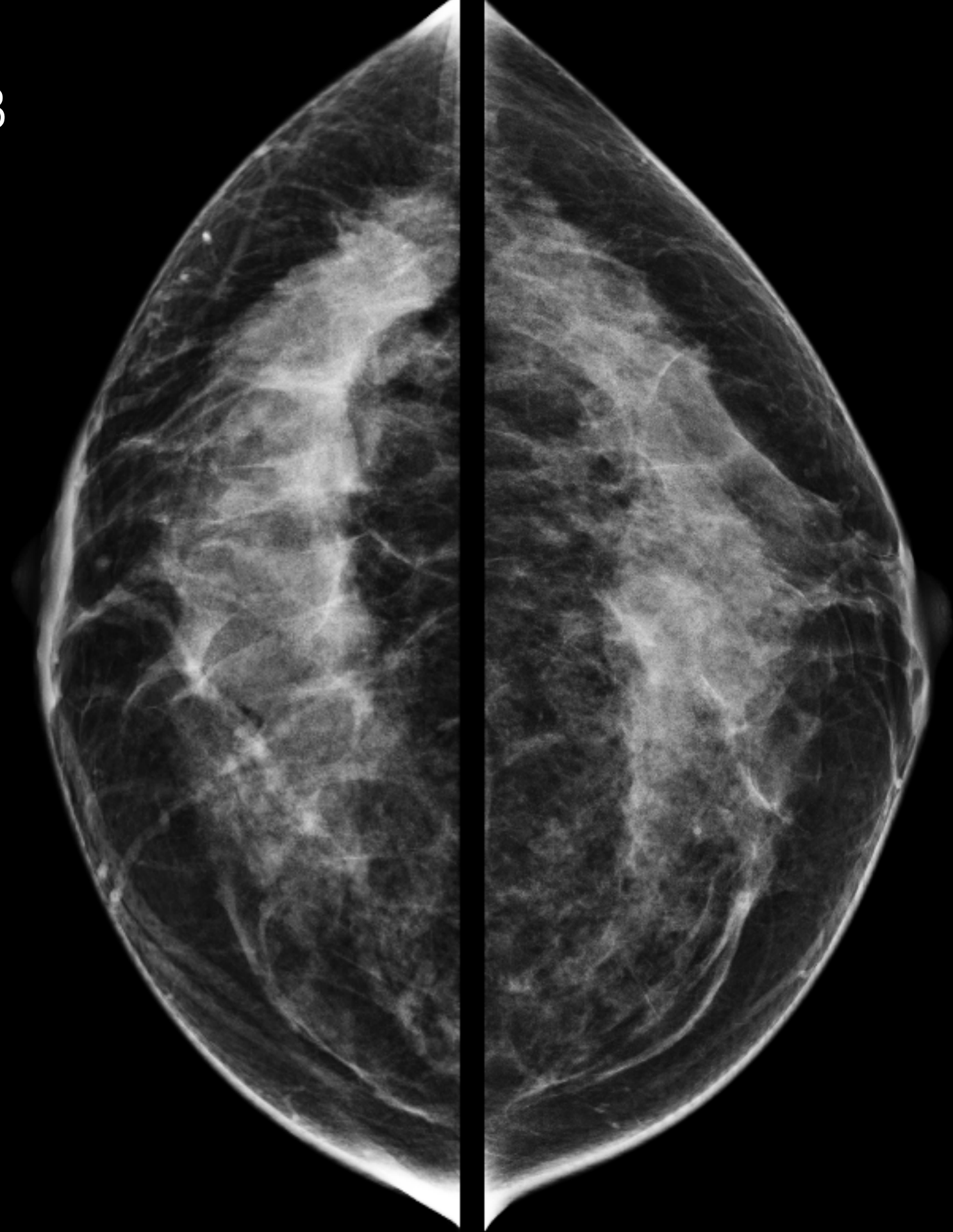


RMLO
LMLO

B
Gen./Med.
M 5/65 dB/Med.
T 1480 m/s
SC/SR 2
G 35 %
Fr. 52 Hz

Z 100 %

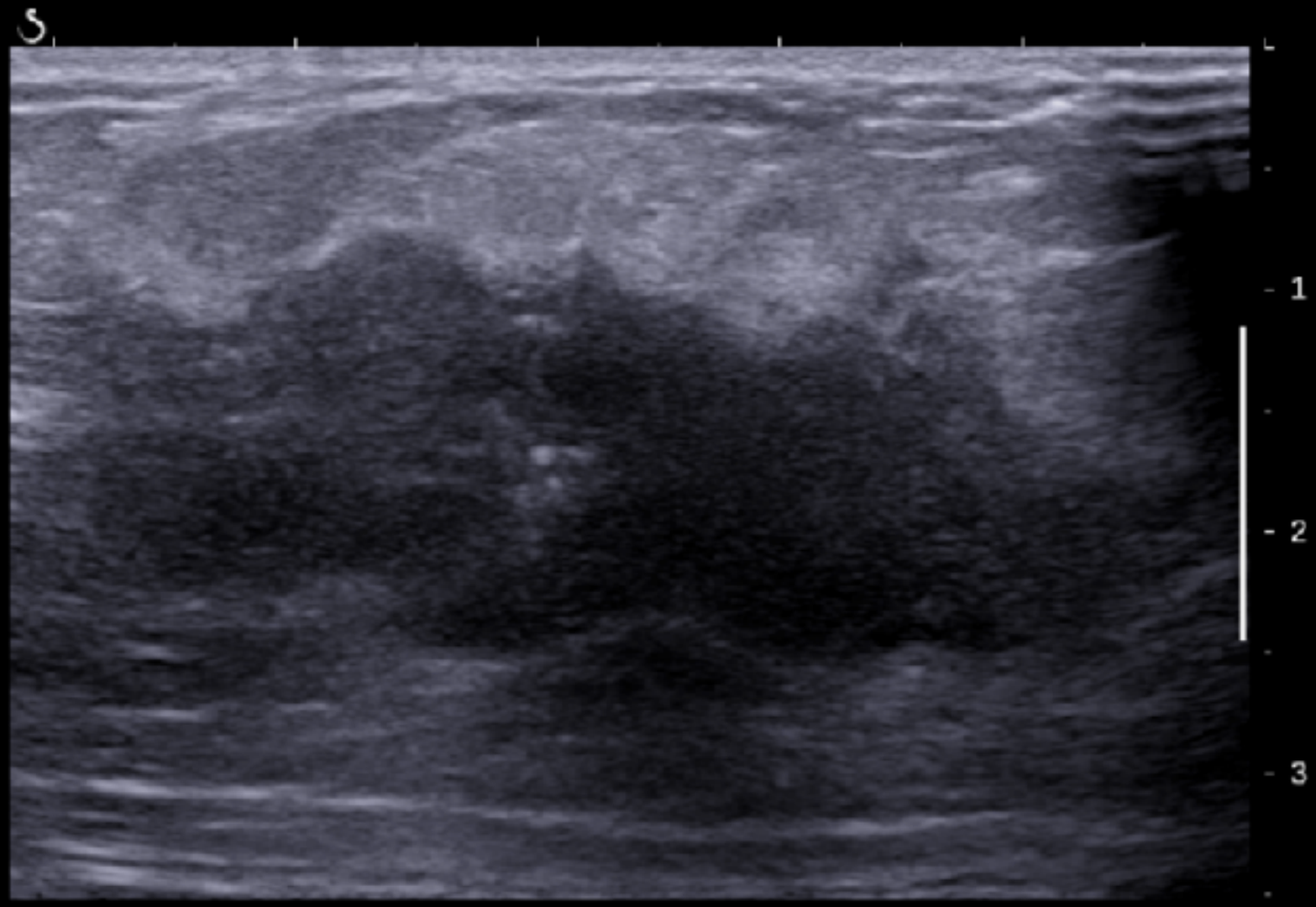

Fr: 4221/4221

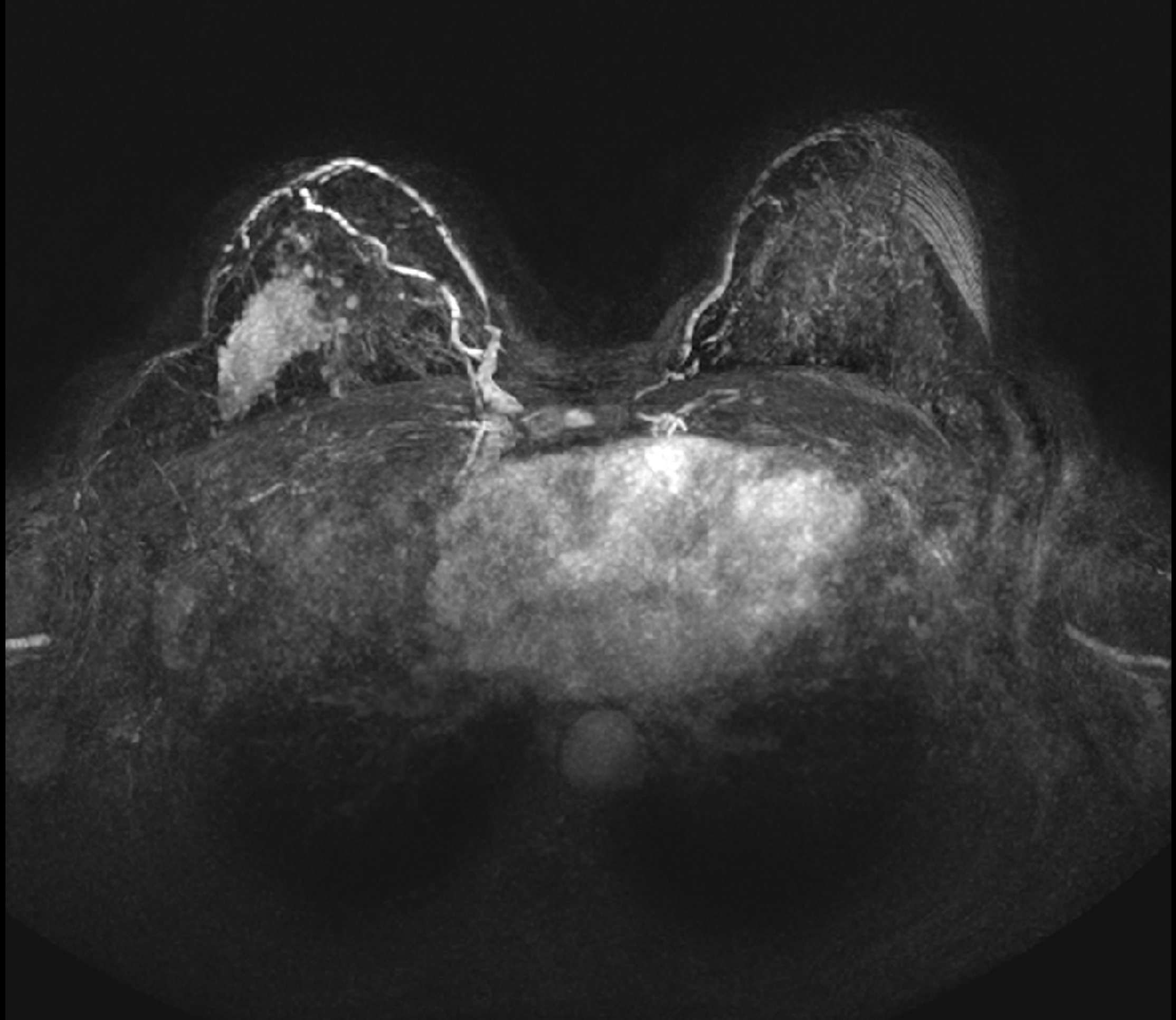

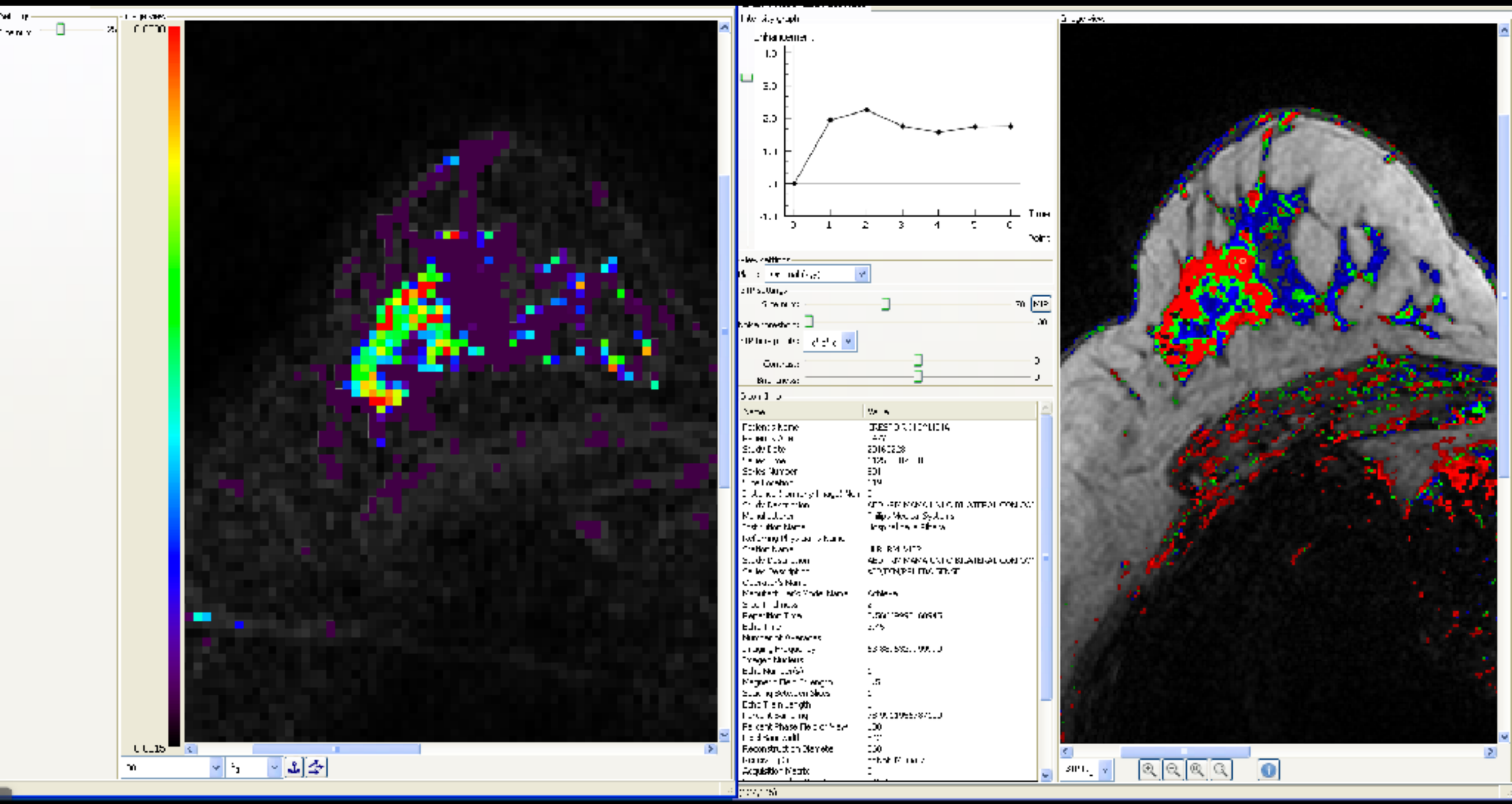

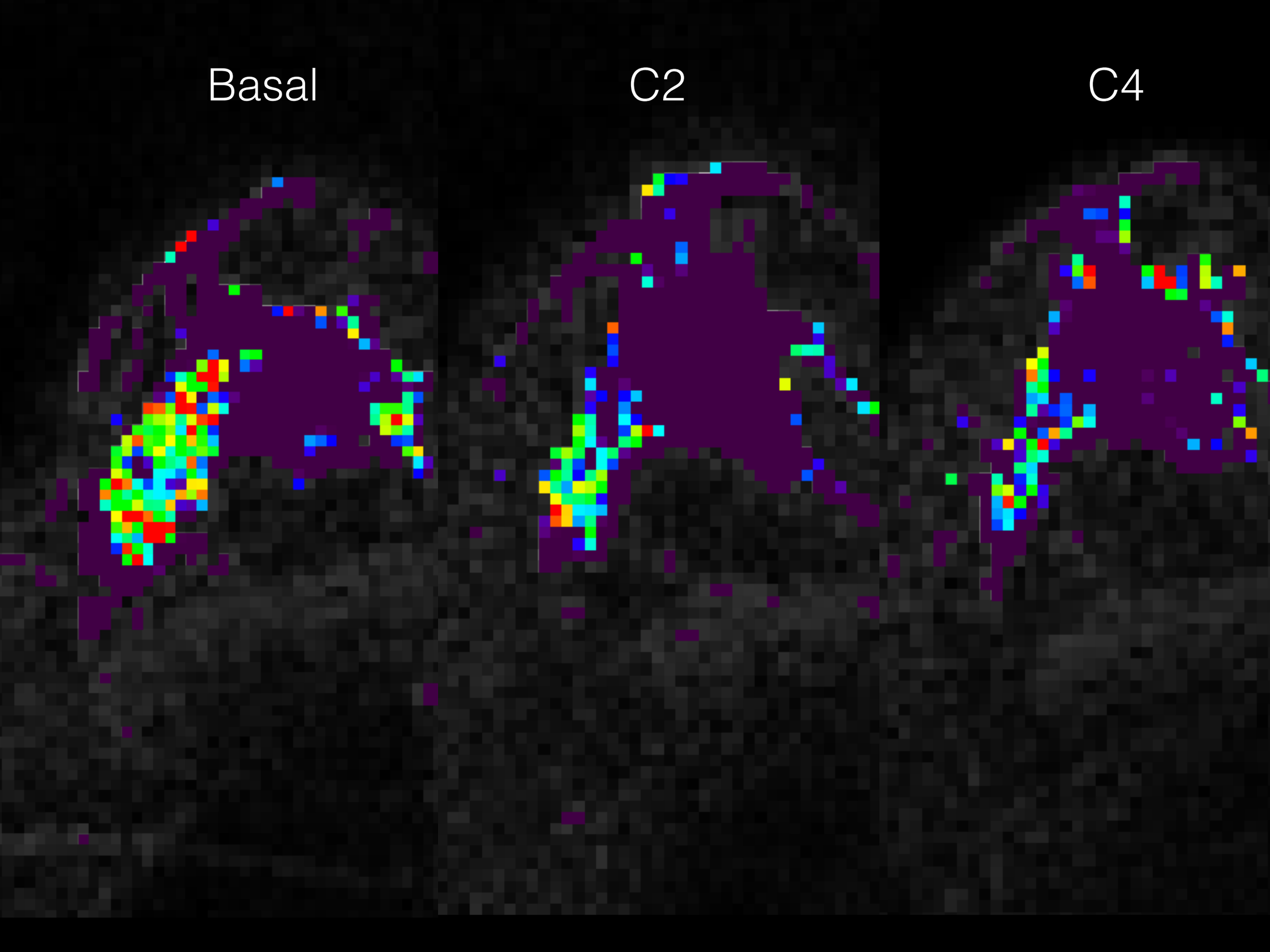
Basal
C2
C4

Basal

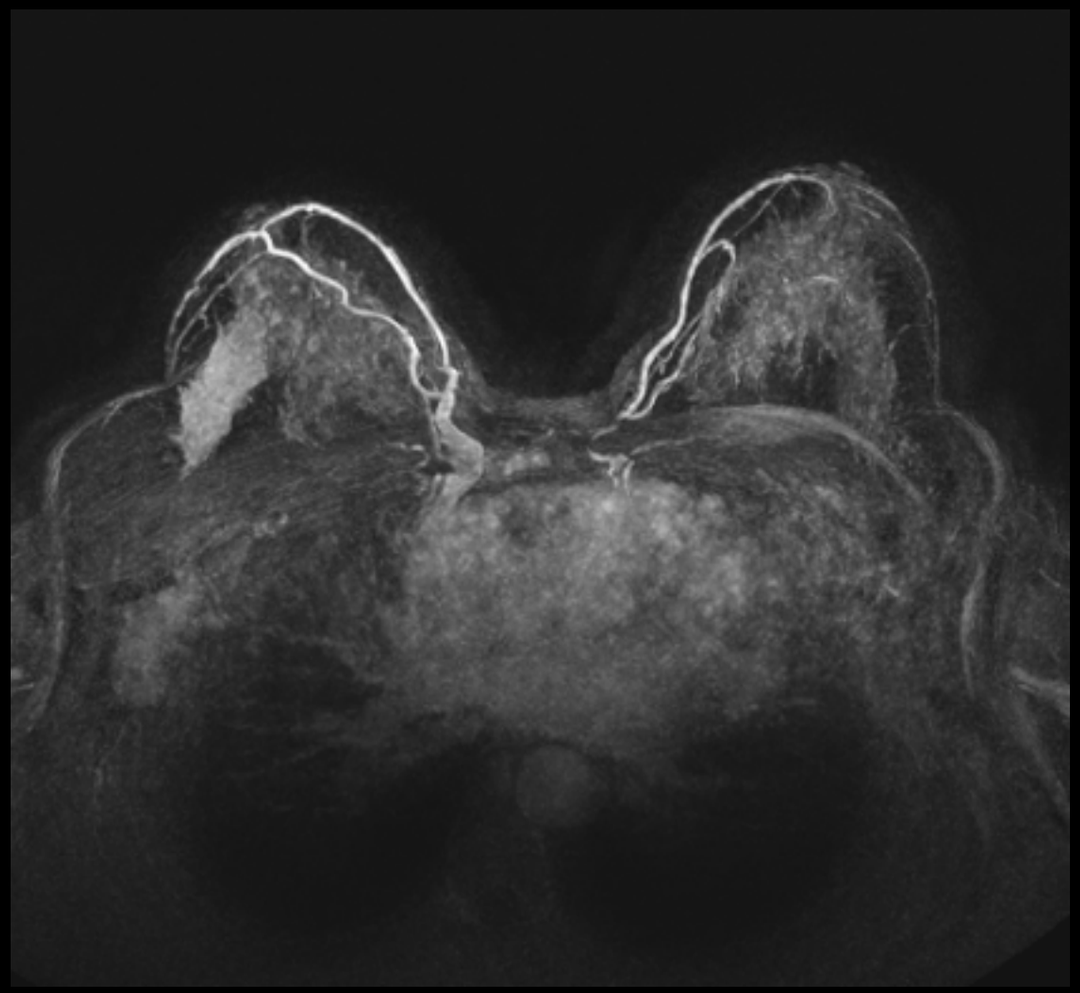

C4

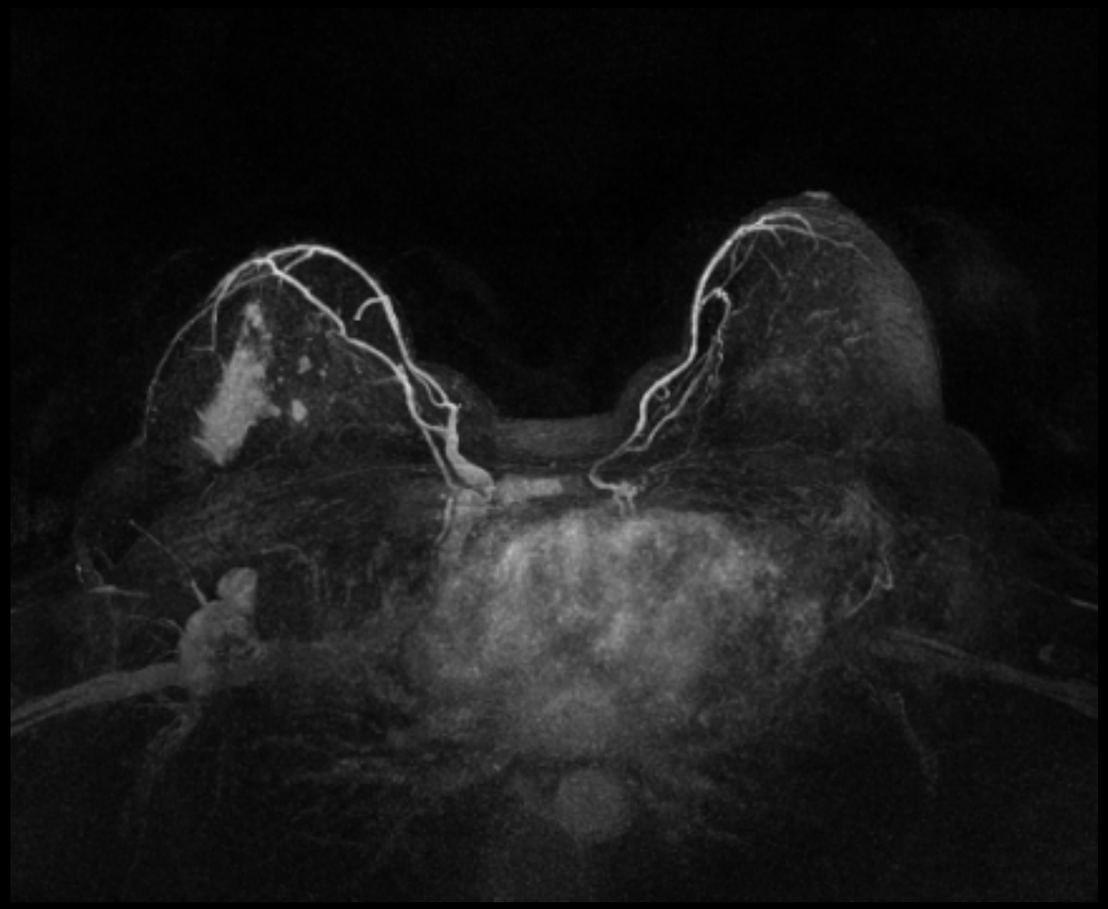

Fragmented Partial Minor Response

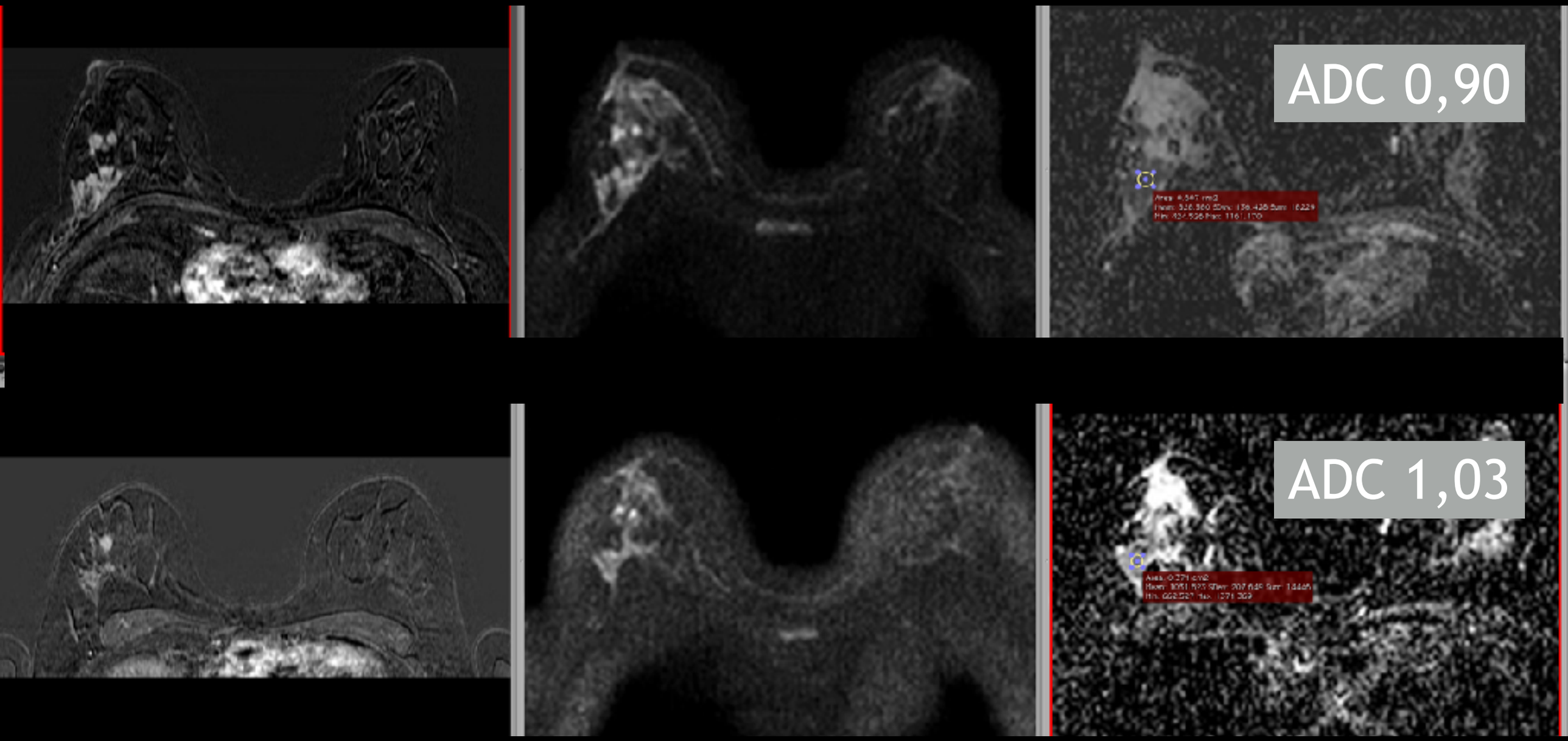

Subtipo HER2

- Tumores multicéntricos, microcalcificaciones
- Lesiones de gran tamaño
- Mamas densas
- RM predice mejor la respuesta a la neoadyuvancia en general en HER2+ que en HER2-

HER2 Mamas Densas

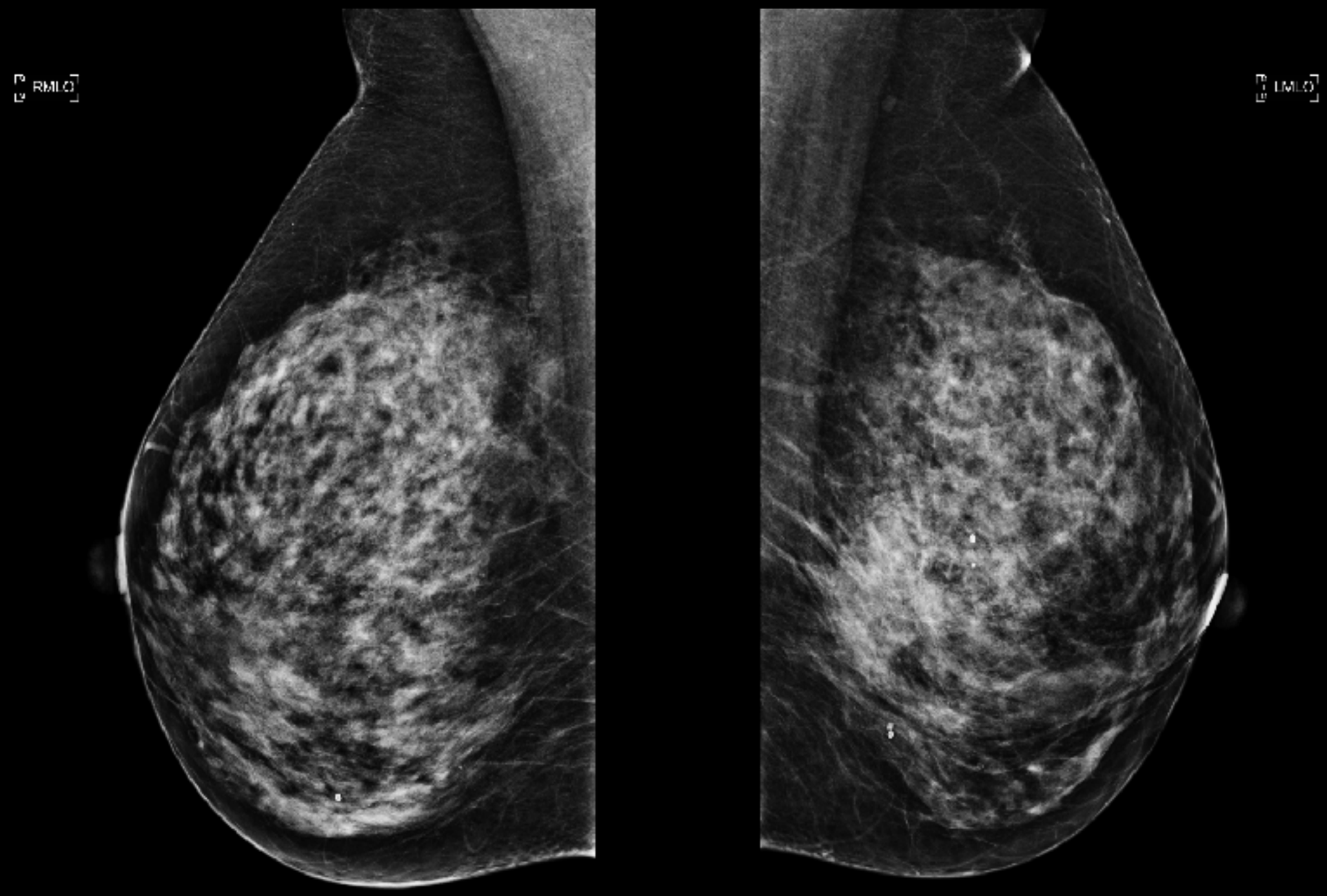

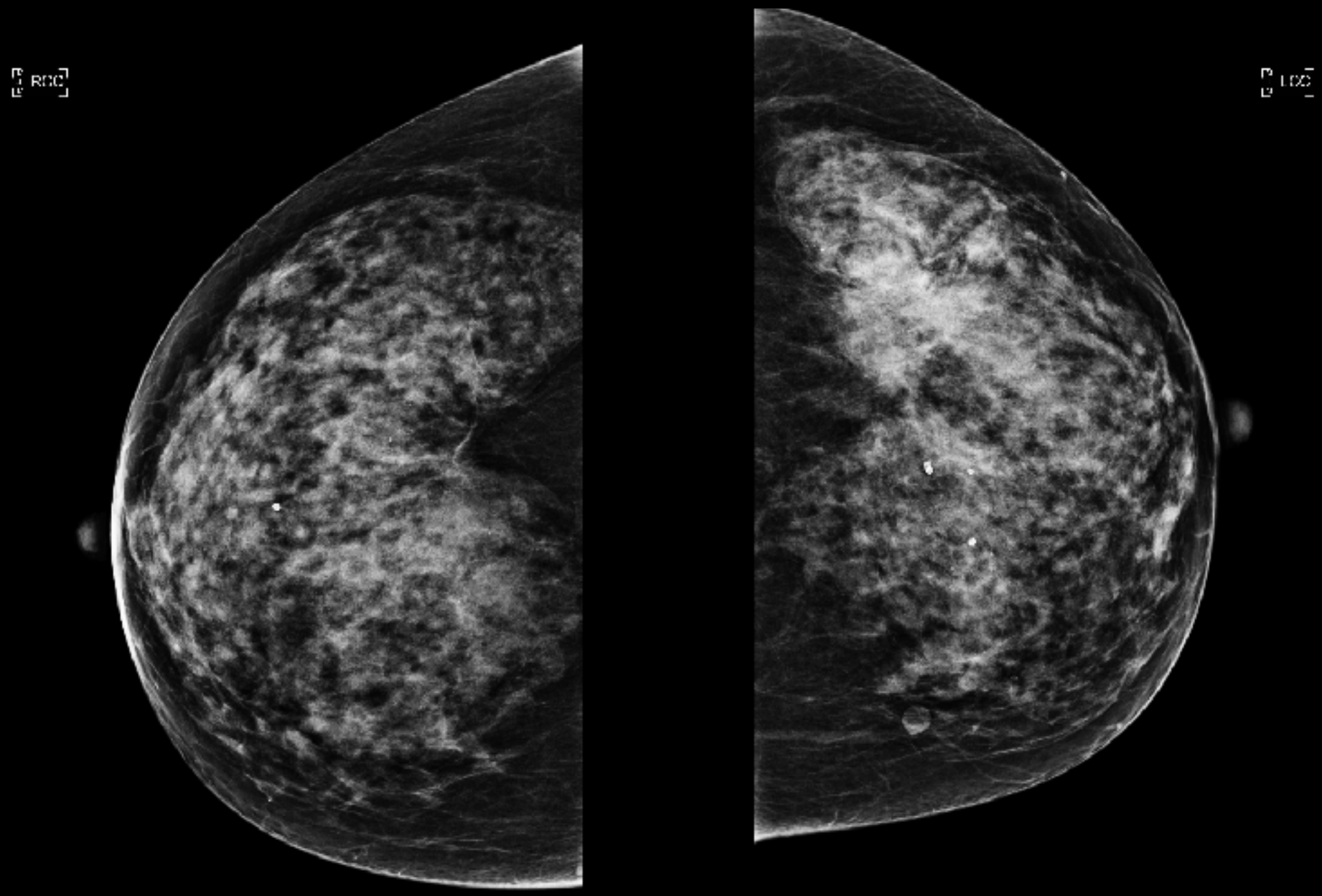
R00
L00

Multifocalidad en HER2

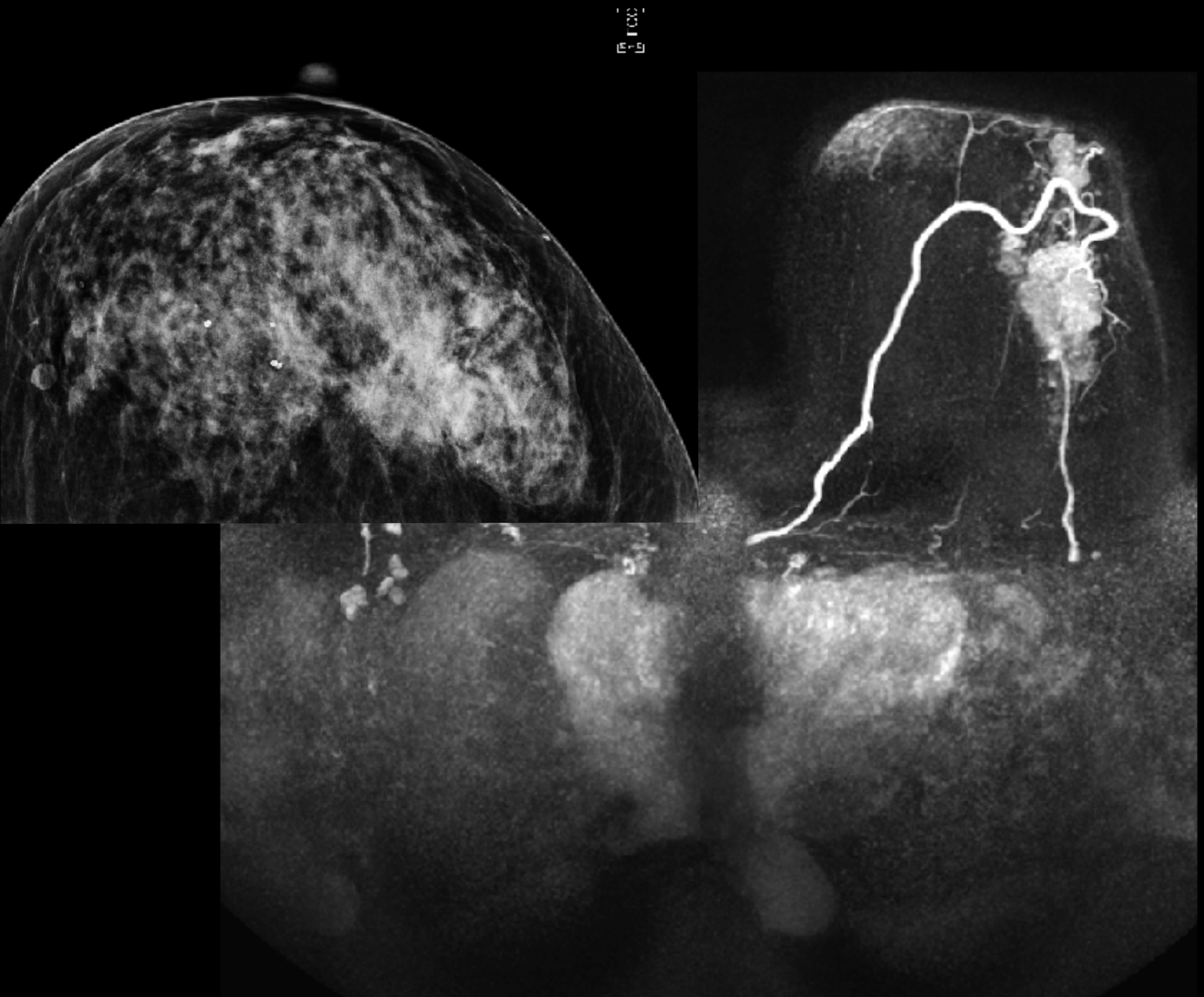

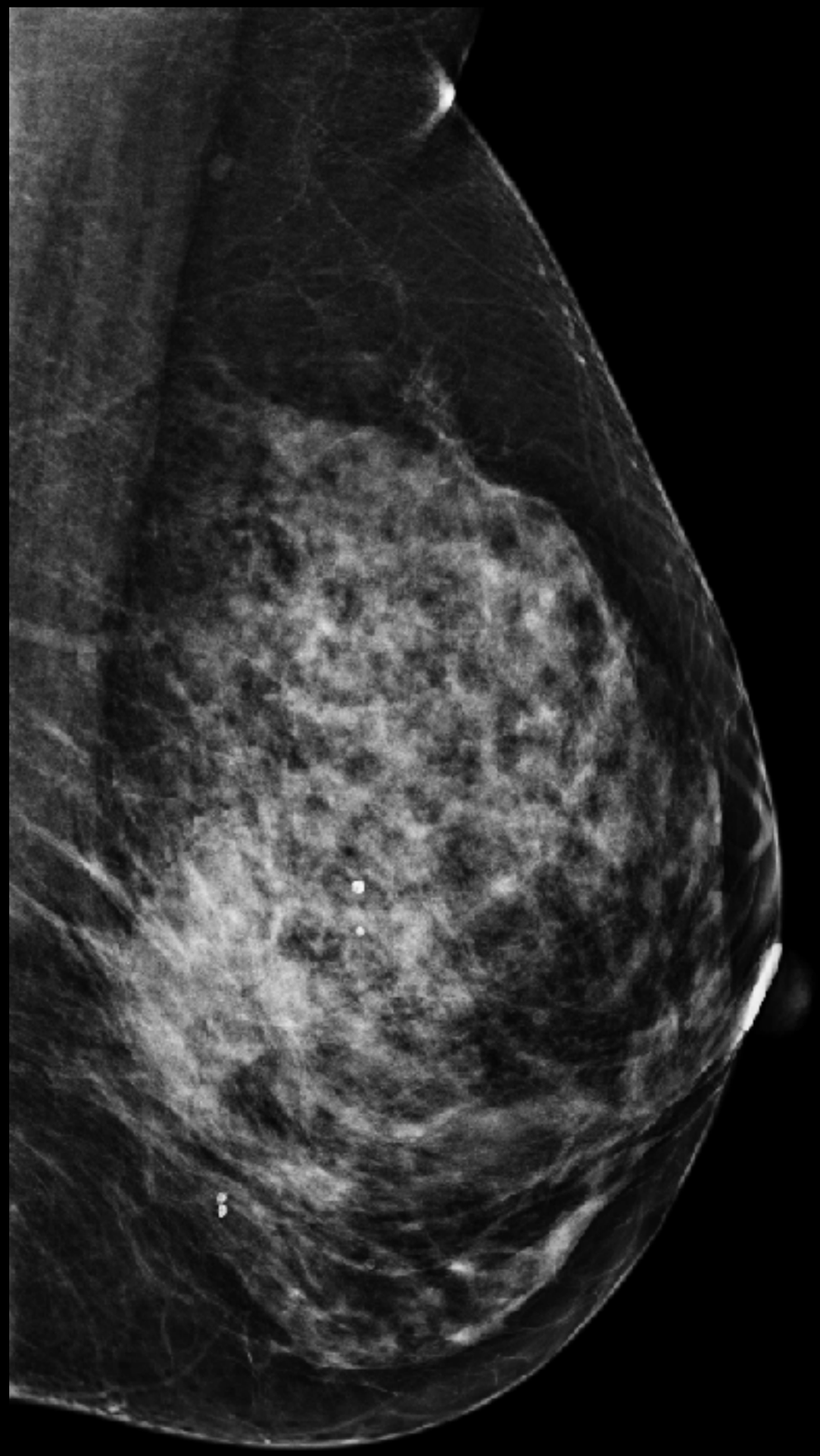
LMLO

Heterogeneidad tumoral

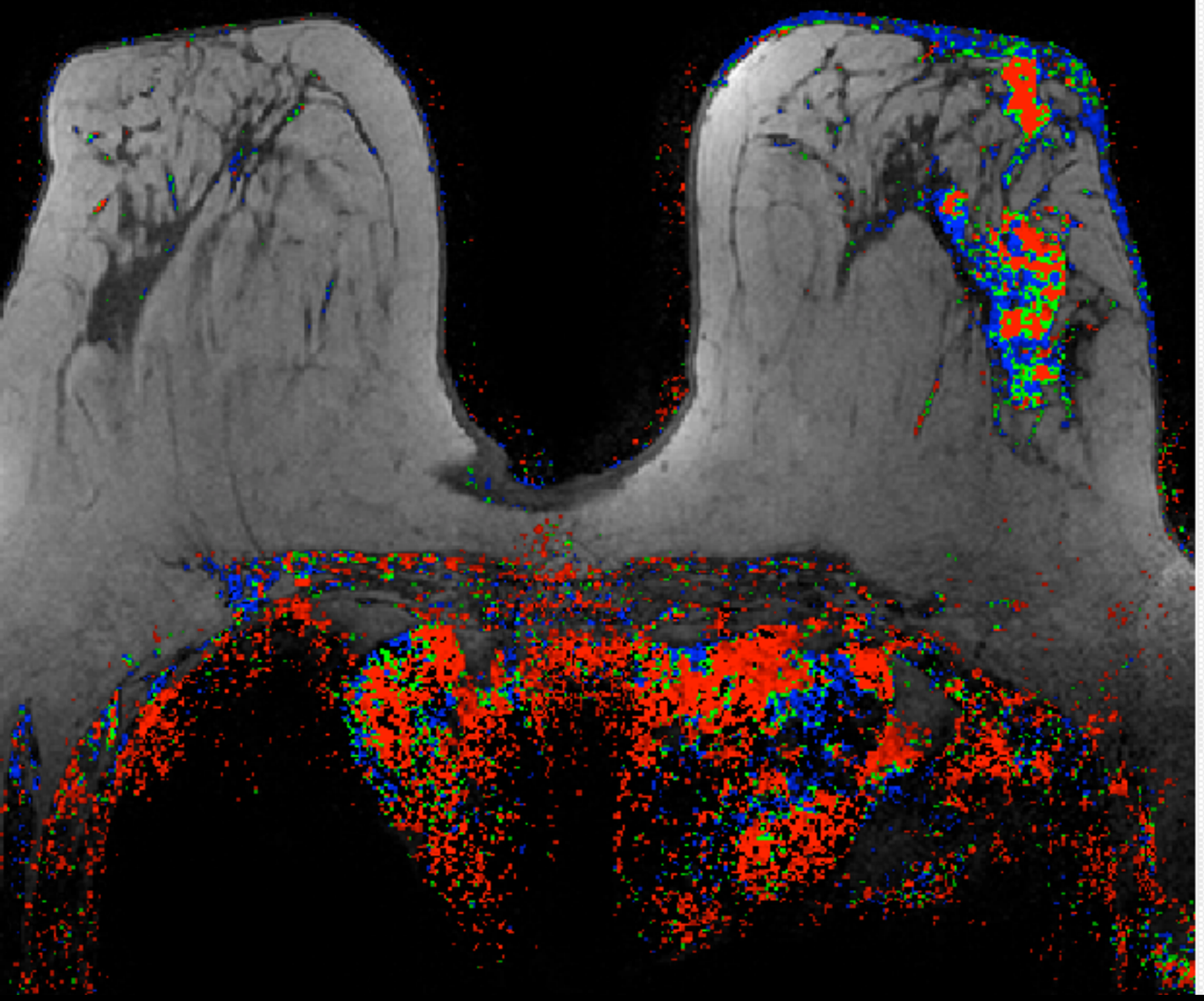

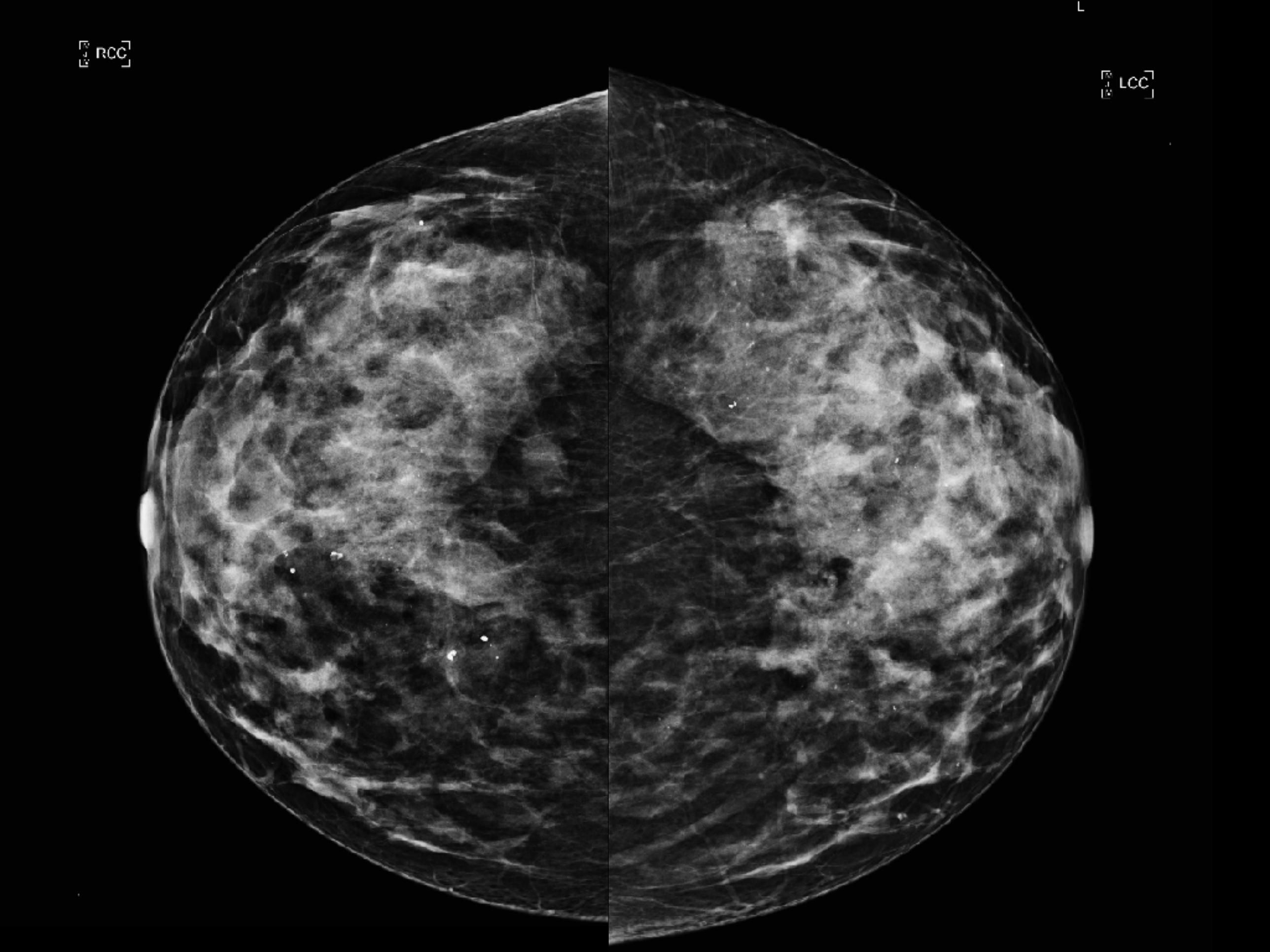
RCC
LCC

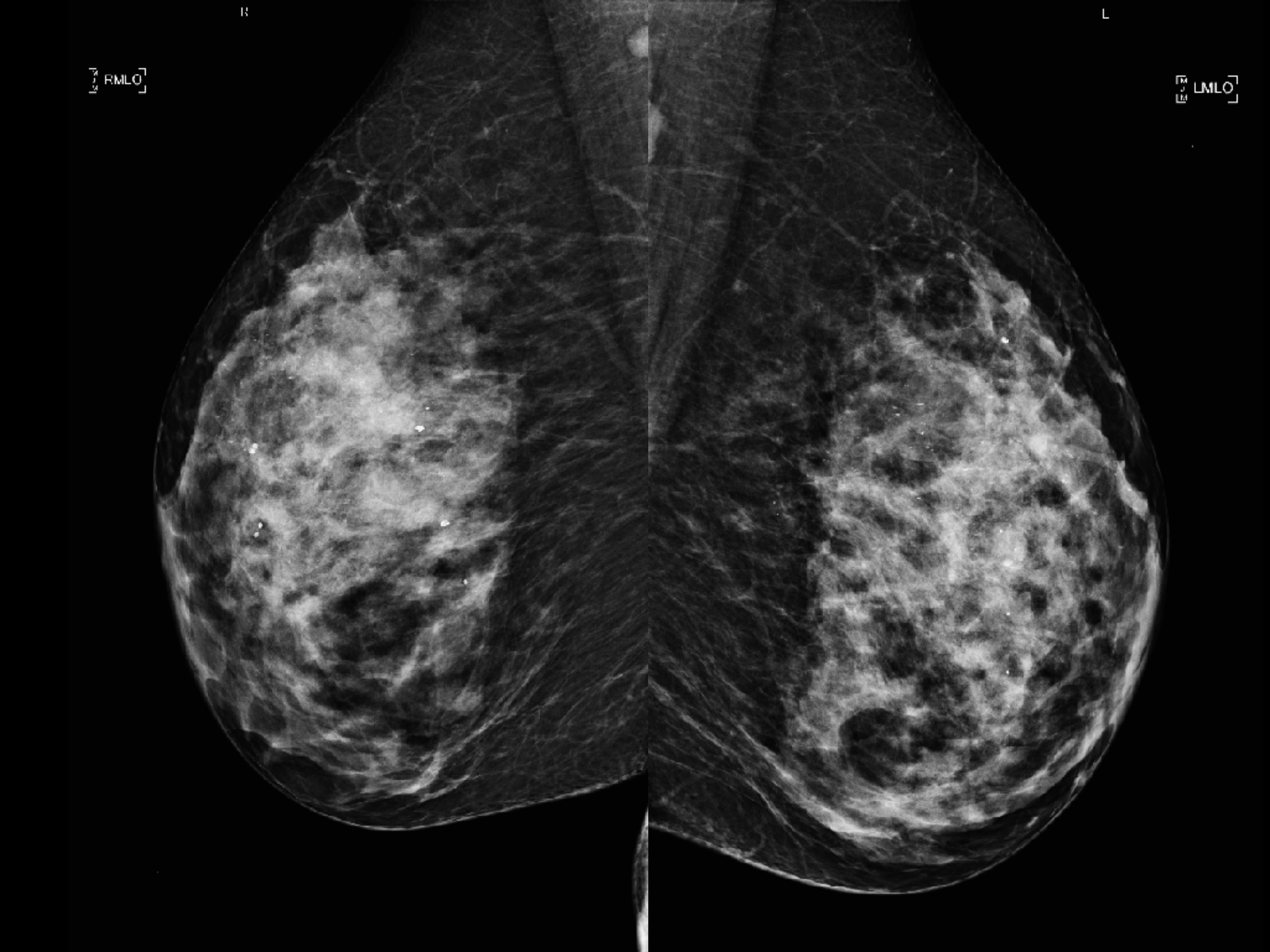
R
L
RMLO
LMLO

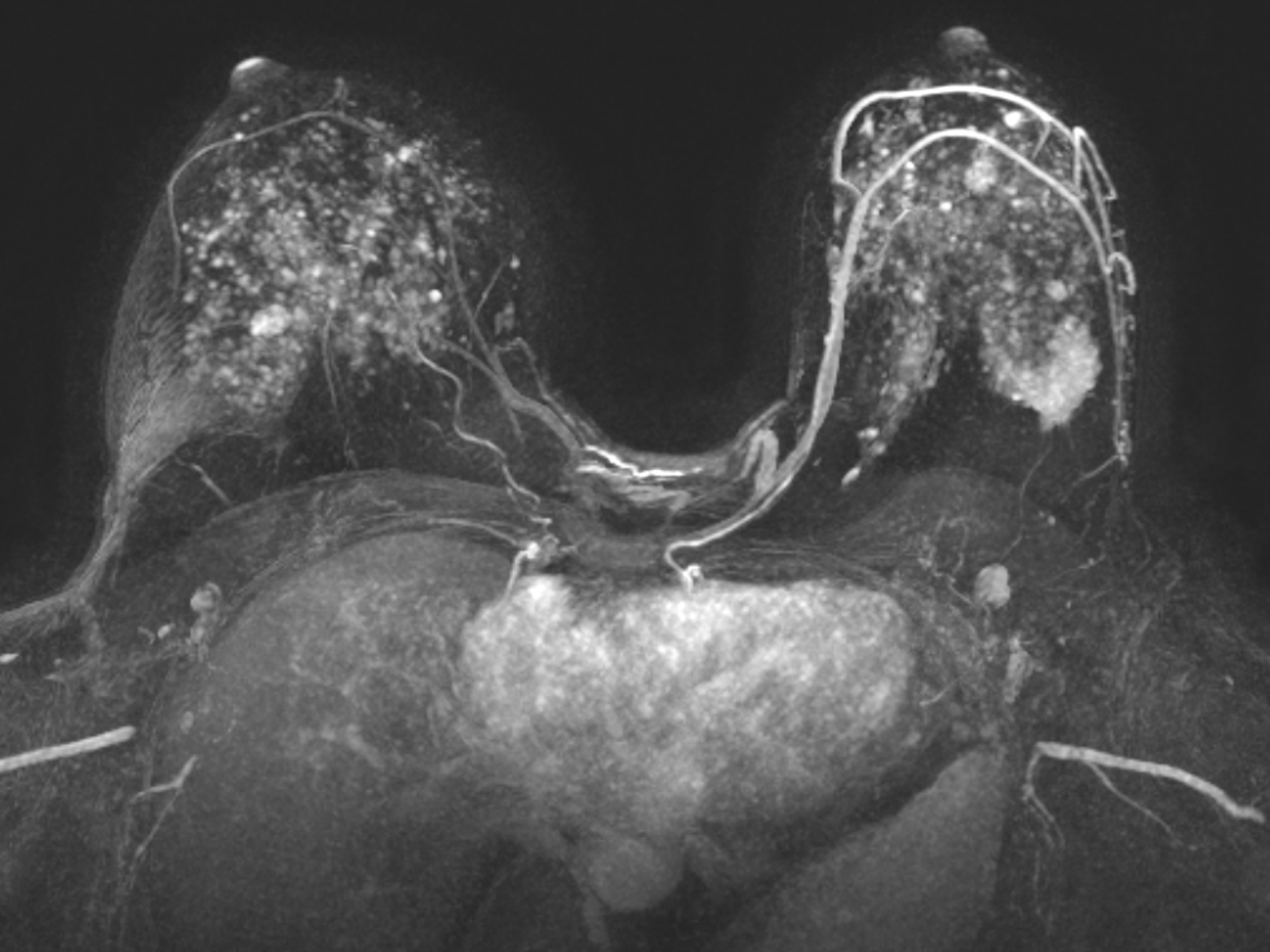

Multicentricidad en HER2

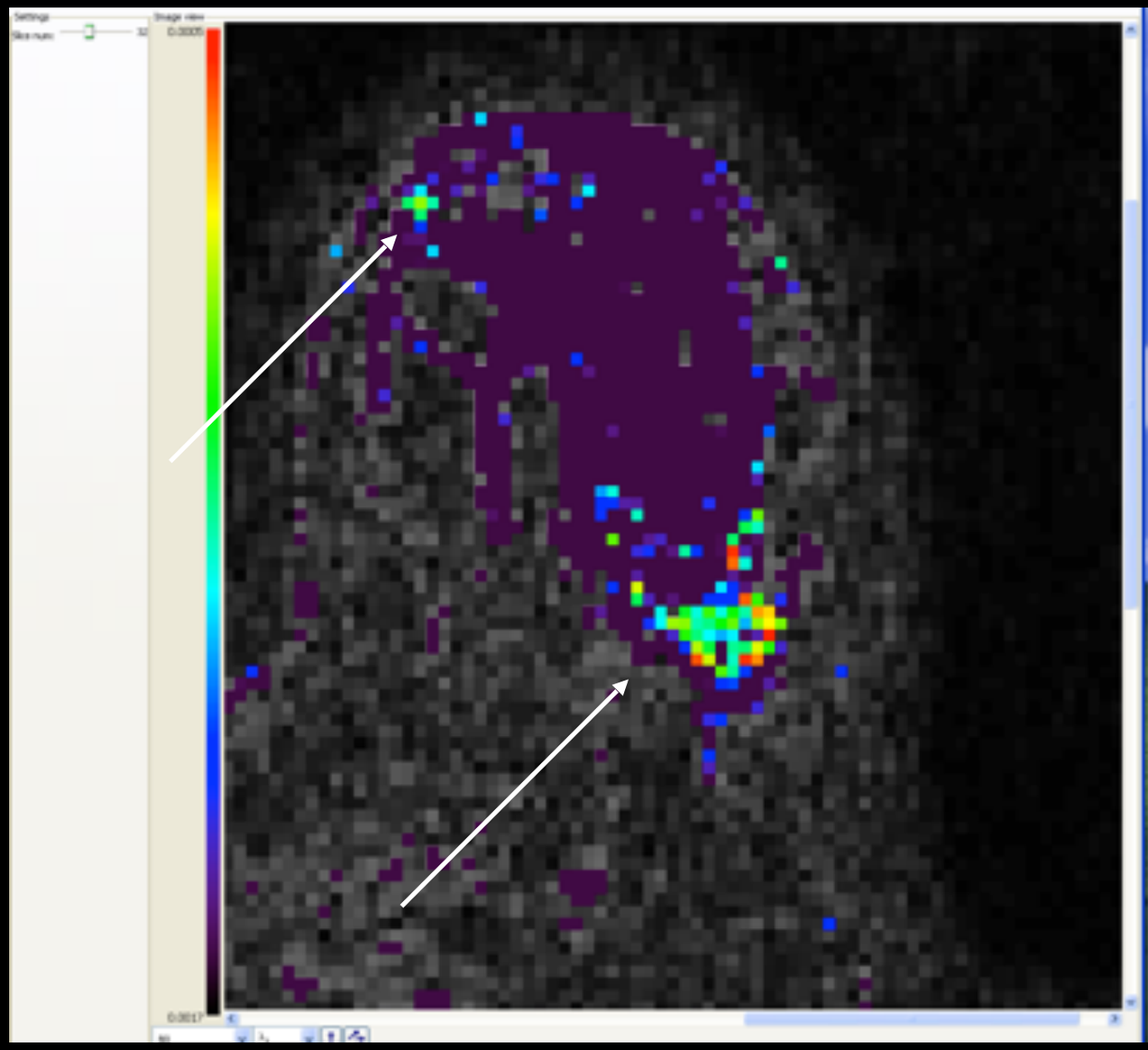

RM-Difusión (DTI)

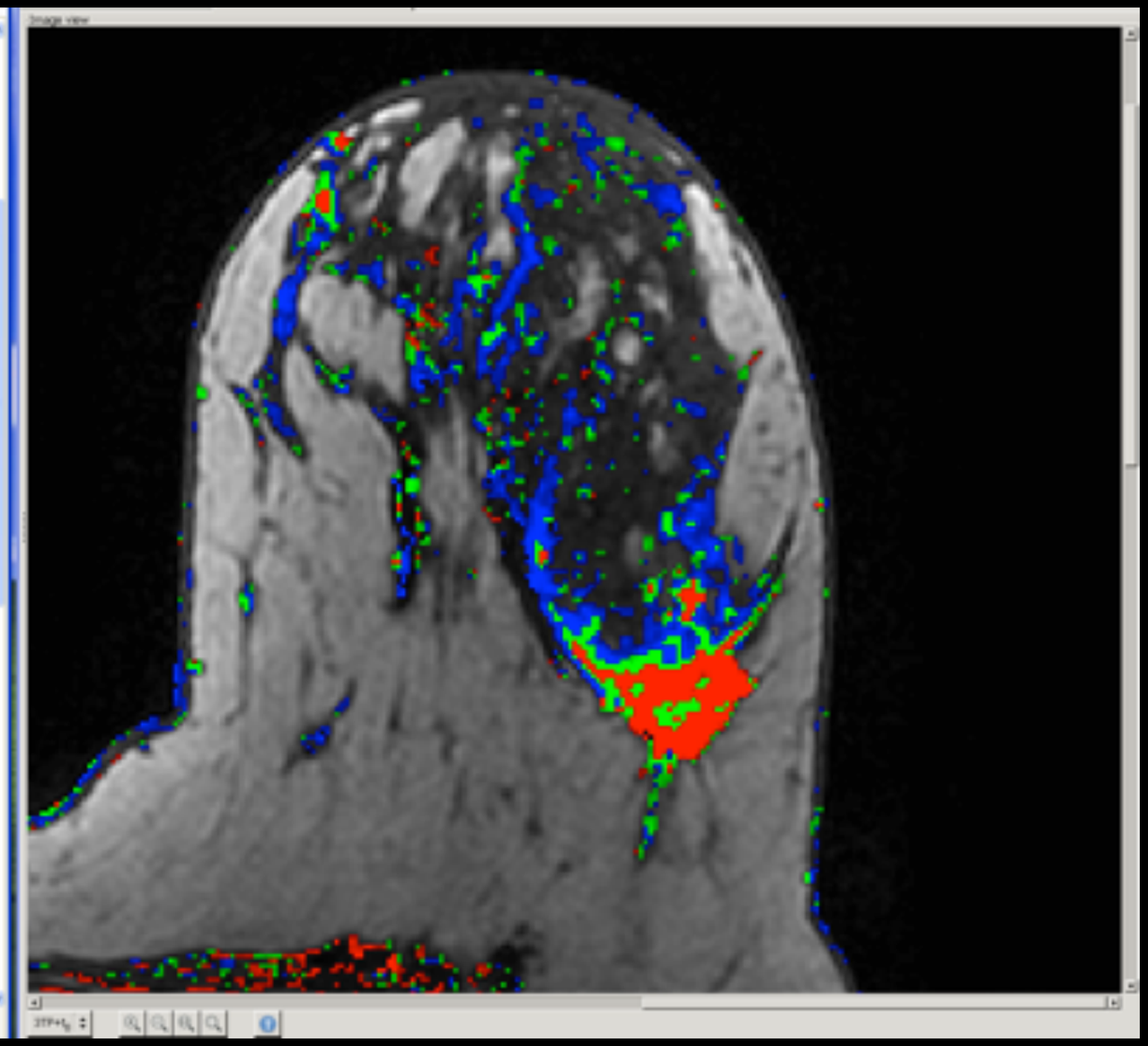

RM-Contraste

Pre NAC

Pre-surgery

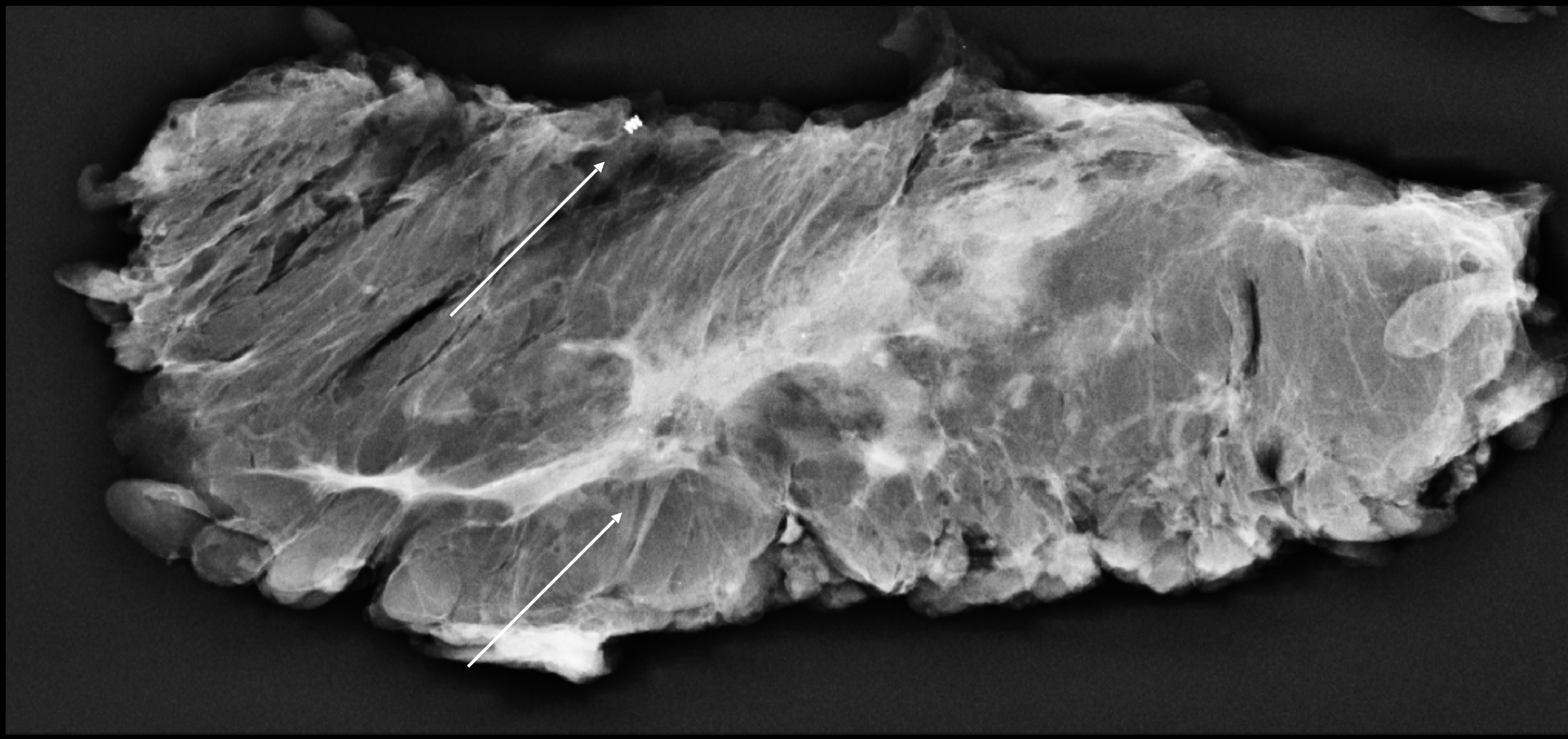

pCR

Triple Negativo

- Necrosis central
- Bordes bien delimitados (ausencia de desmoplasia)
- Crecimiento rápido (tiempo de duplicación tumoral 45 días)

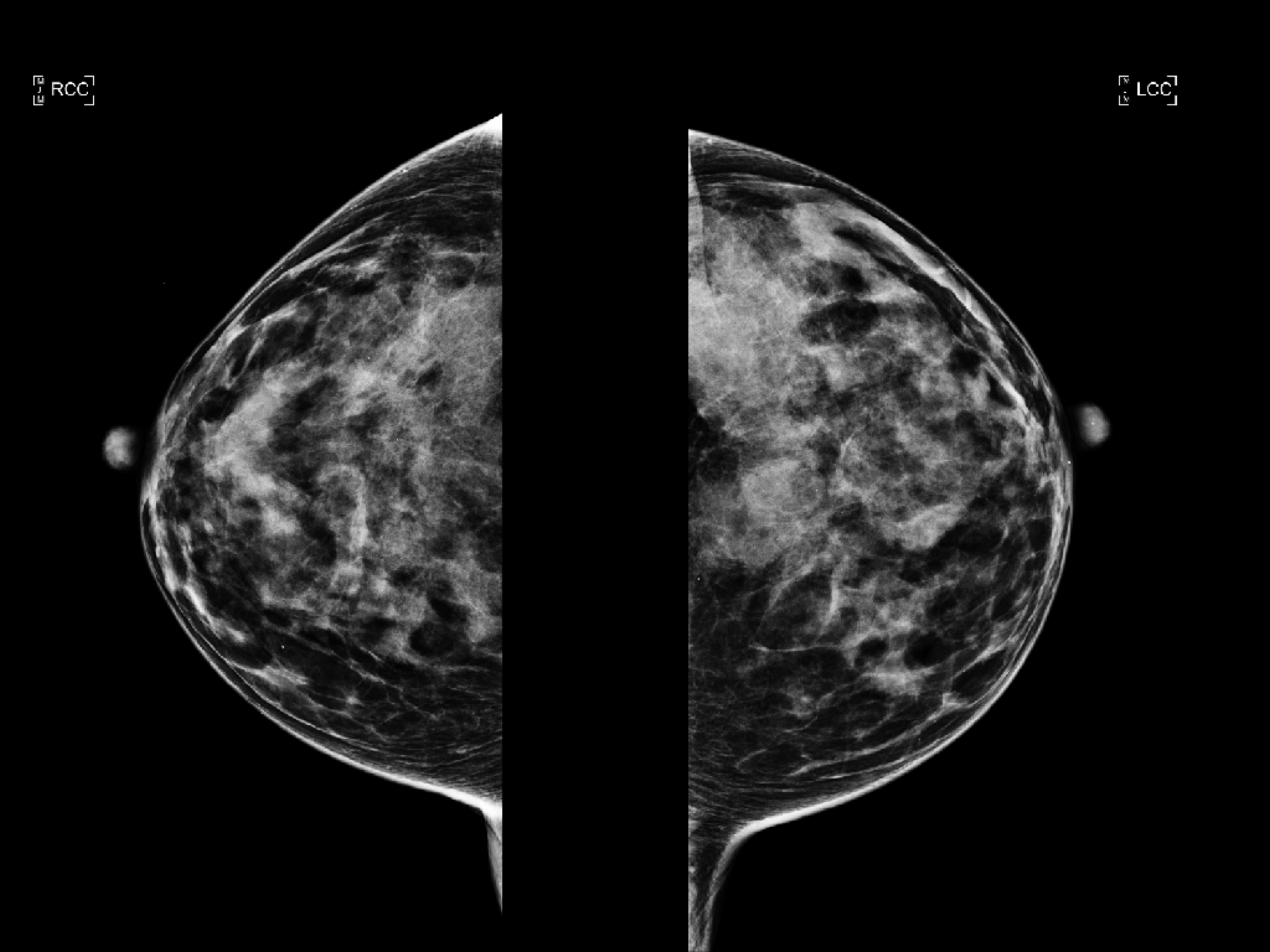
RCC
LCC

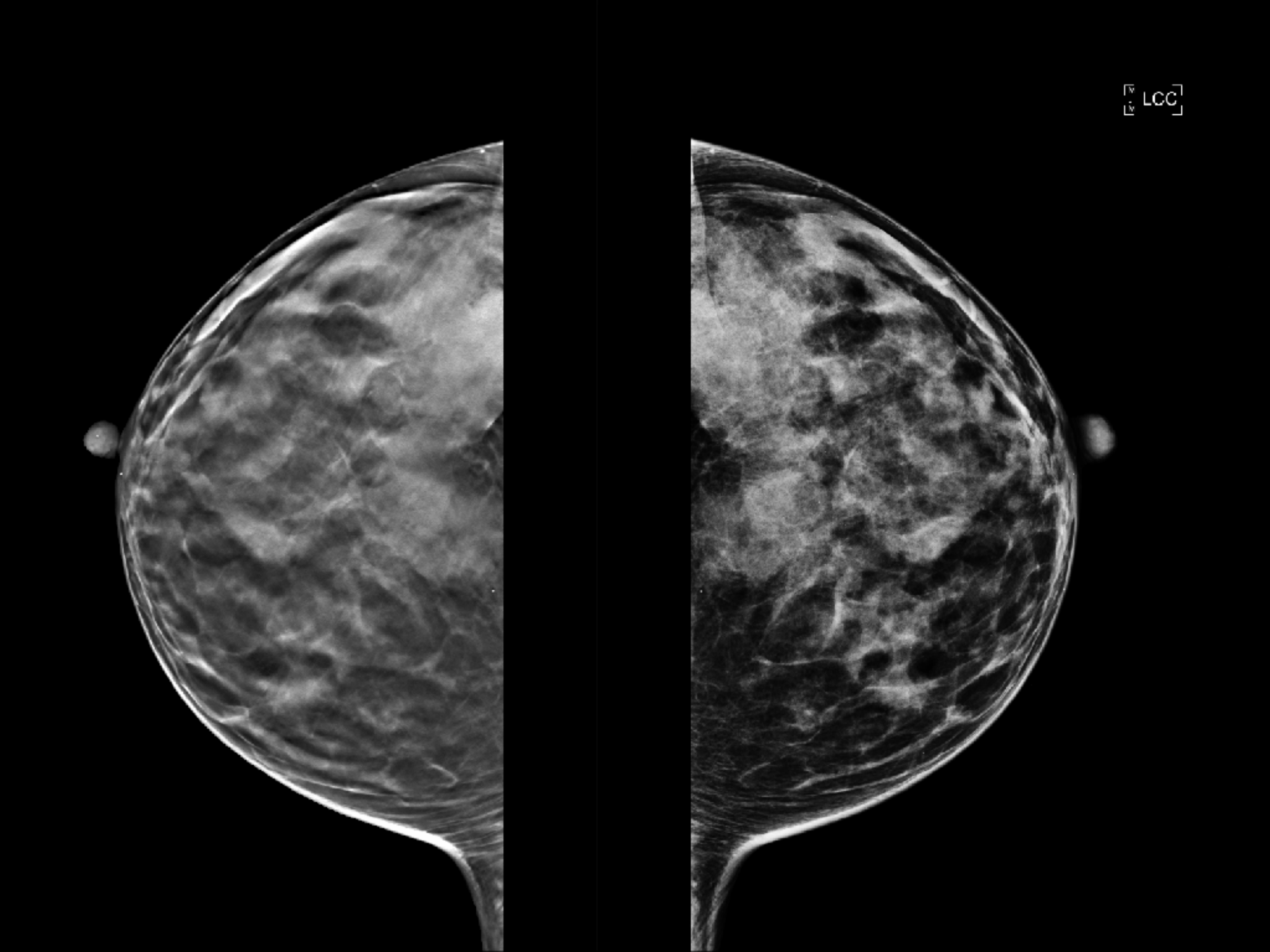
LCC

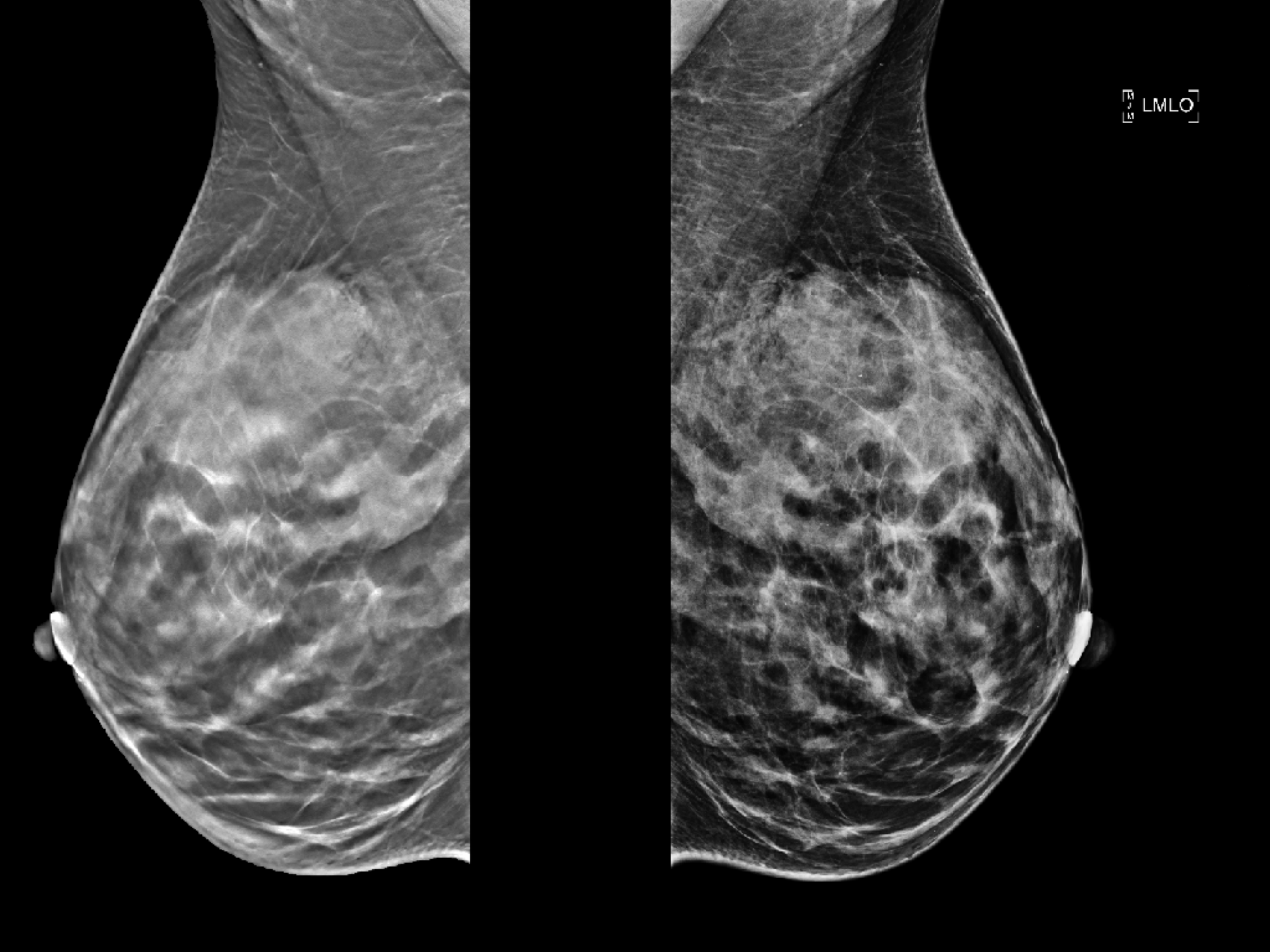
LMLO

ed.
dB/Med.
m/s
2

z

6

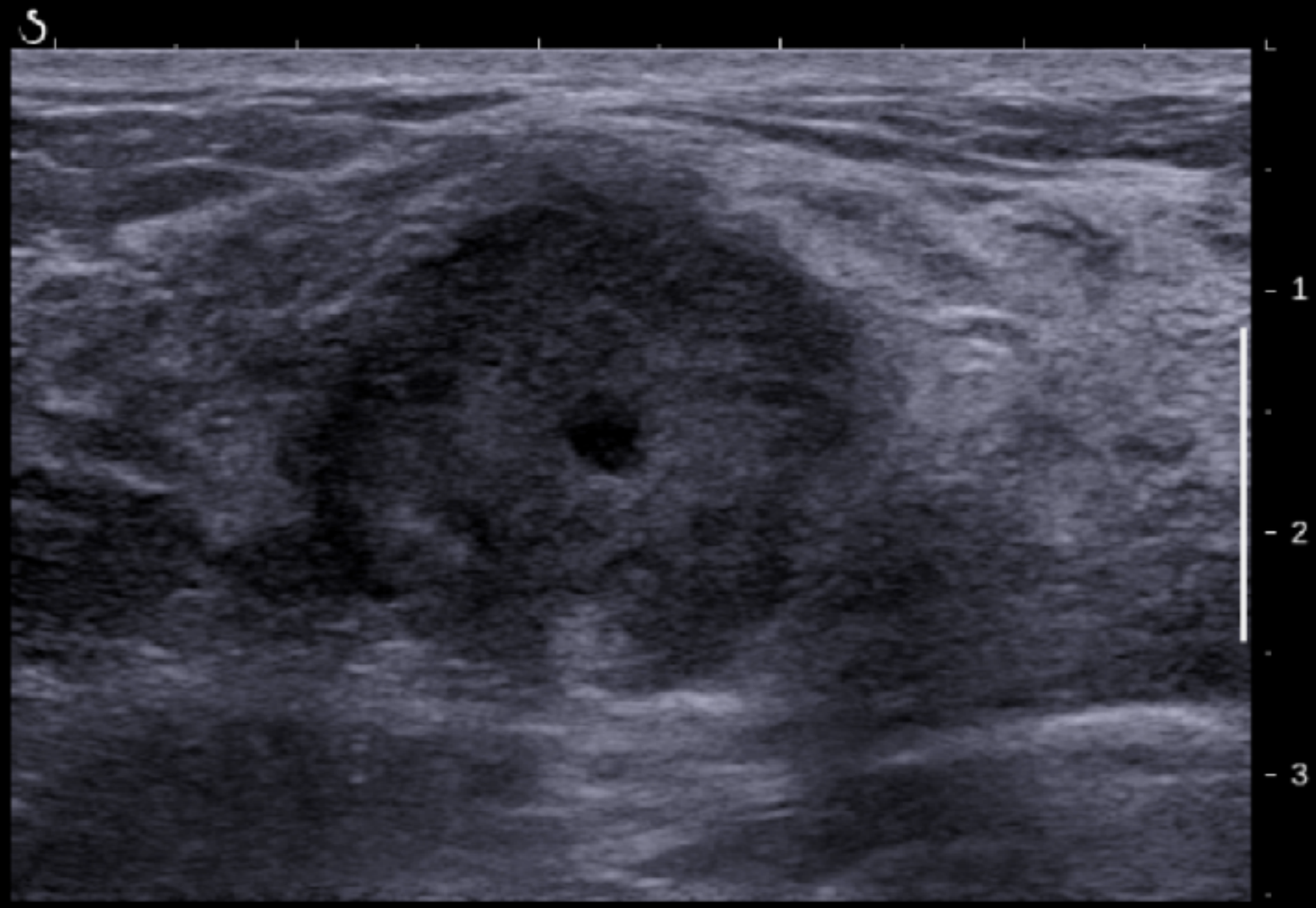

06

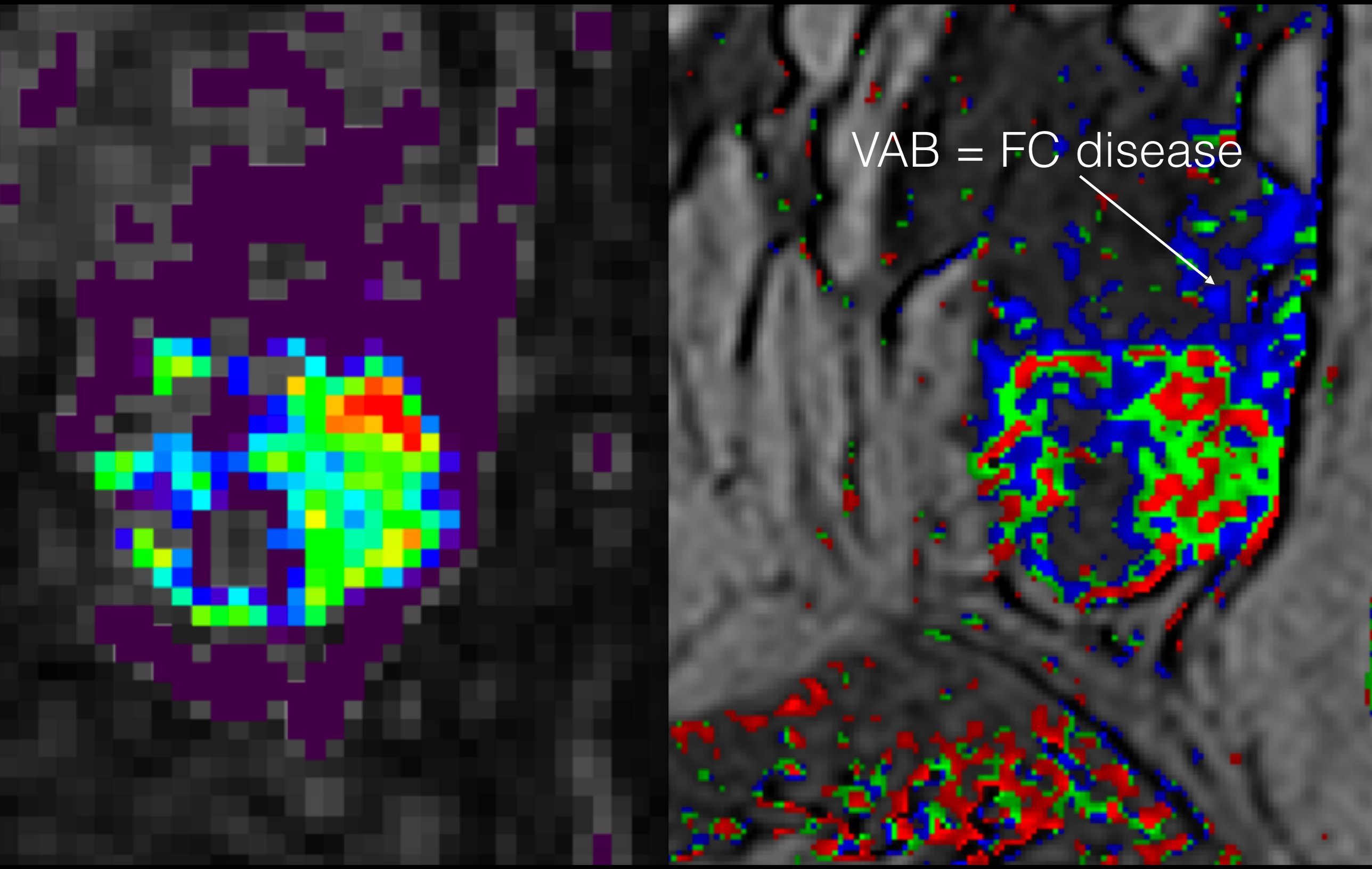
VAB = FC disease

Basal

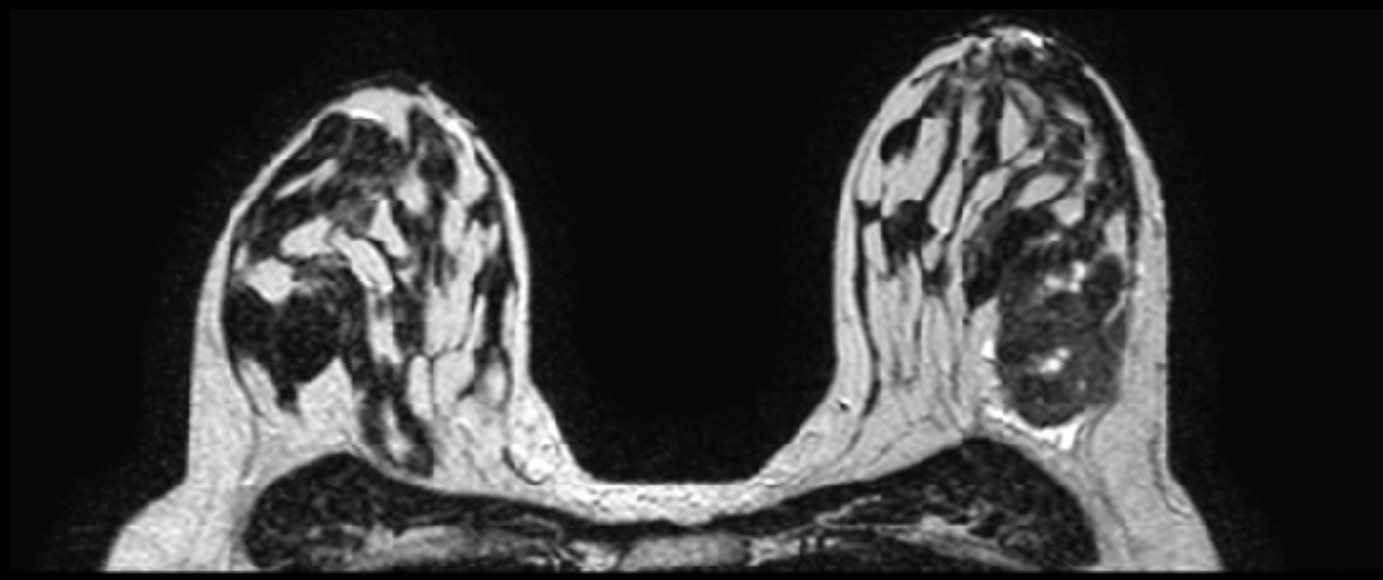

2C precoz

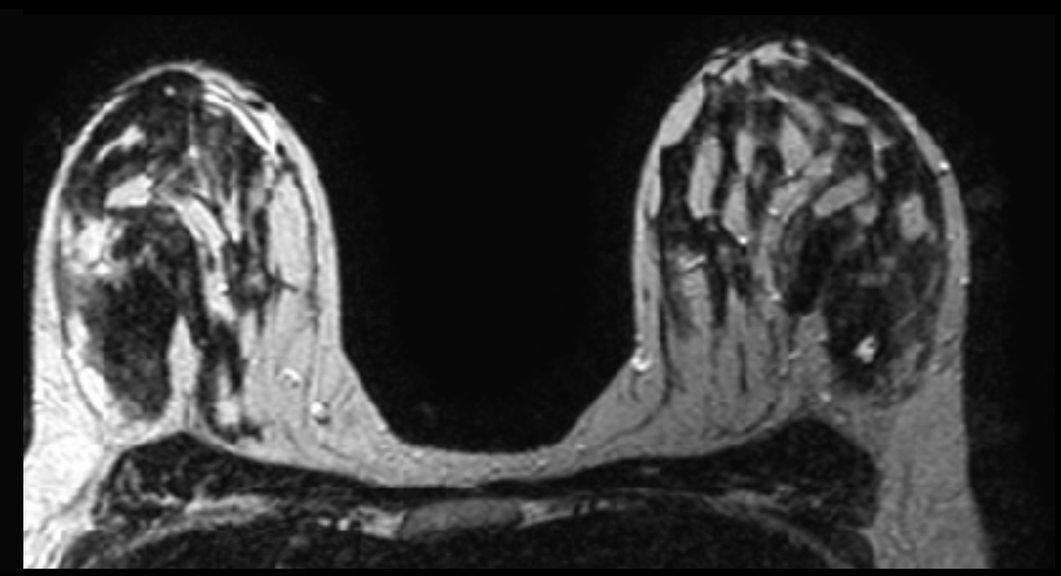

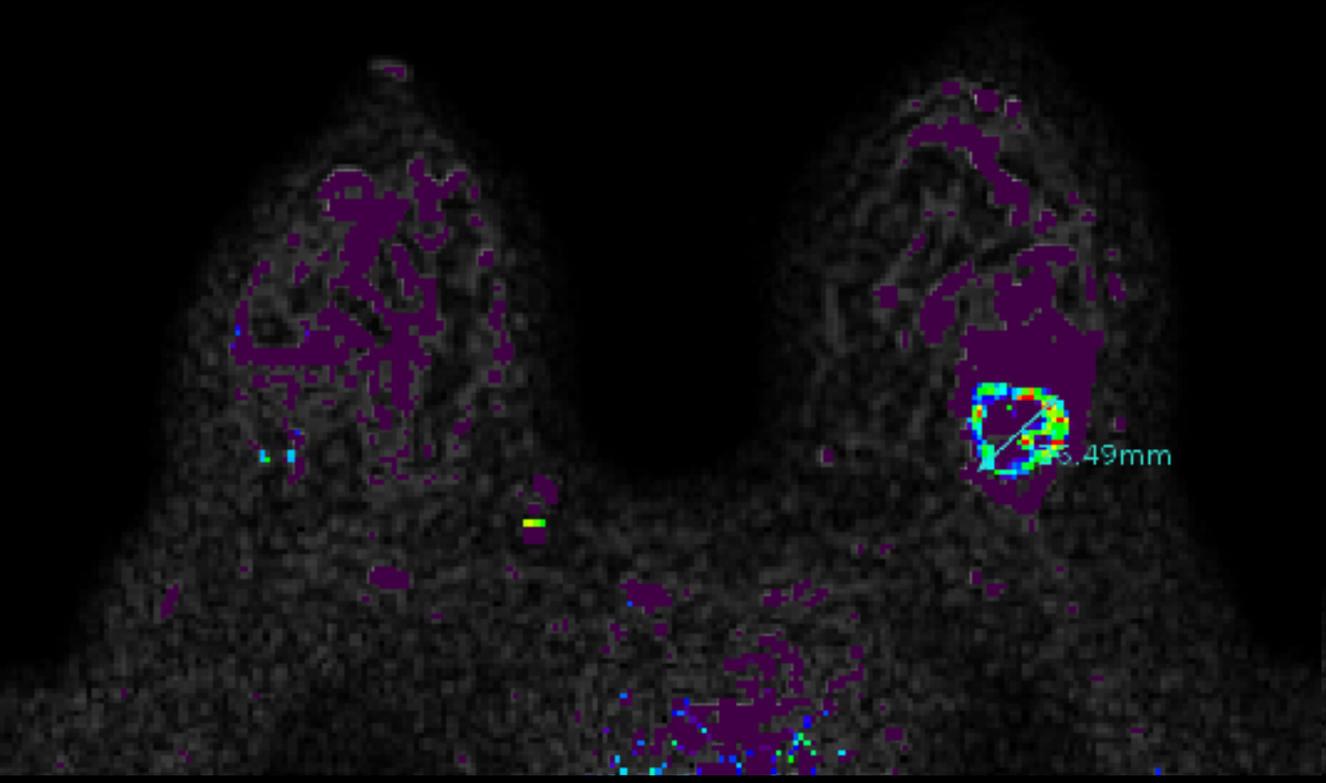

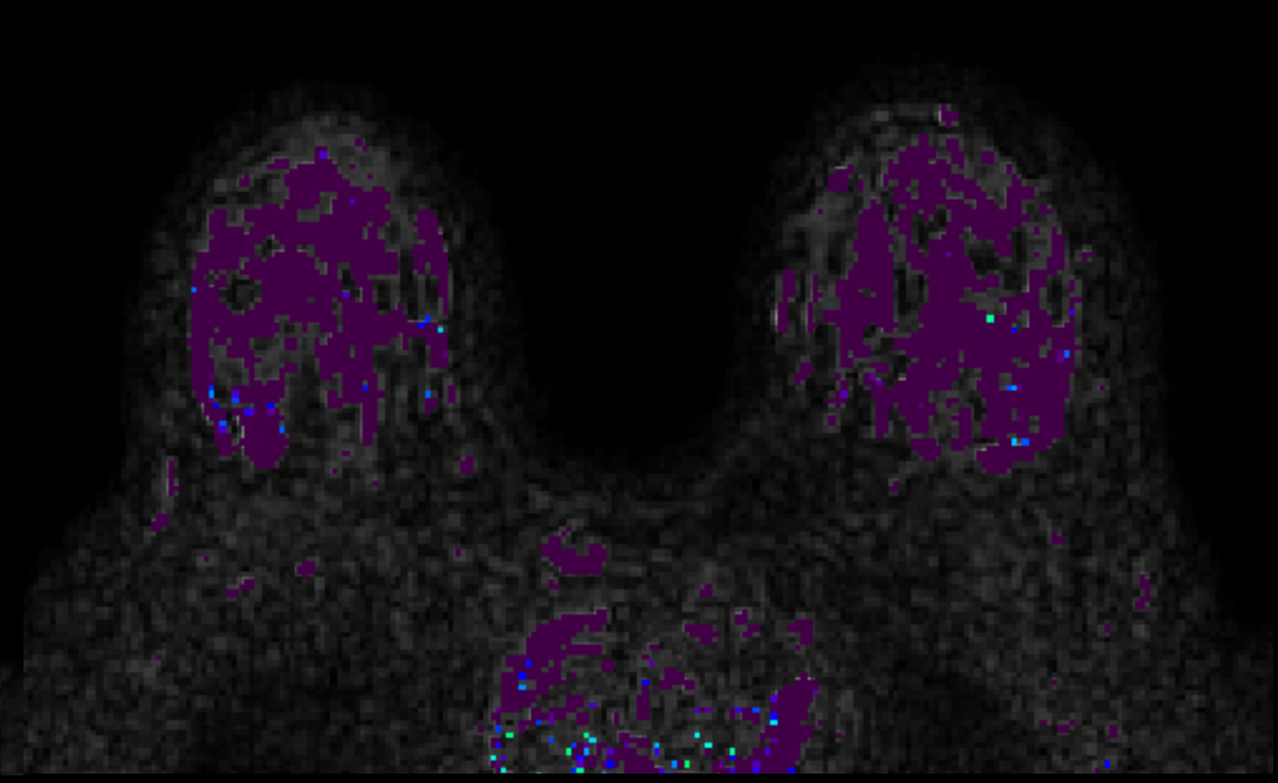

Available online at www.sciencedirect.com

ScienceDirect

Magnetic Resonance Imaging 24 (2006) 843–847

MAGNETIC RESONANCE IMAGING

Diffusion changes precede size reduction in neoadjuvant treatment of breast cancer

Martin D. Pickles*, Peter Gibbs, Martin Lowry, Lindsay W. Turnbull

Centre for Magnetic Resonance Investigations, Division of Cancer, Postgraduate Medical School, University of Hull, HU3 2JZ Hull, UK

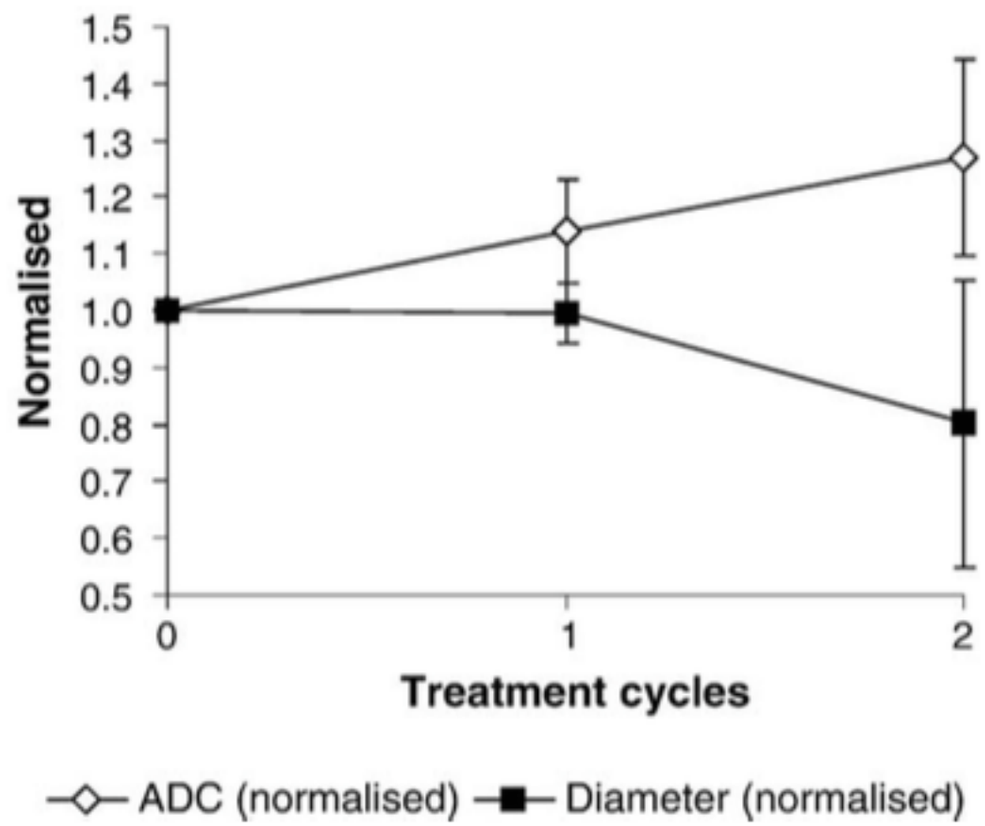

Fig. 2. Normalized mean and standard deviation ADC and longest diameter measures prior to and after the first and second cycle of treatment. Vertical bars represent ±standard deviations.

- Changes in ADC can be found after only one cycle of NAC, with even a more pronounced increase after two cycles*
- DWI is a sensitive biomarker capable of predicting early cellular changes in treated tumors*, which precede macroscopic volumetric response because functional properties of tissues (cellularity in DWI) change before the manifestation of structural changes (diameter and volume)

*- Pickles, M. D., Gibbs, P., Lowry, M., & Turnbull, L. W. (2006). Diffusion changes precede size reduction in neoadjuvant treatment of breast cancer. Magnetic Resonance Imaging, 24(2006), 843–847.
- Sharma, U., Danishad, K. K. A., Seenu, V., & Jagannathan, N. R. (2008). Longitudinal study of the assessment by MRI and diffusion-weighted imaging of tumor response in patients with locally advanced breast cancer undergoing neoadjuvant chemotherapy. NMR in Biomedicine, 22(2009), 104–113.
- Jensen, L. R., Garzon, B., Heldahl, M. G., Bathen, T. F., Lundgren, S., & Gribbestad, I. S. (2011). Diffusion-weighted and dynamic contrast-enhanced MRI in evaluation of early treatment effects during neoadjuvant chemotherapy in breast cancer patients. Journal of Magnetic Resonance Imaging : JMRI, 34(5), 1099–1109.

European Congress of Radiology

ECR 2016

Vienna

March 2–6

Diffusion tensor imaging (DTI) is an accurate and solid imaging biomarker for early response evaluation to neoadyuvant chemotheraphy

E. Garcia Oliver, J. Camps Herrero, M. Forment Navarro,
V. Ricart Selma, E. Furman-Haran, N. Nissan, H. Degani

La Ribera
Departamento de Salud

TUMOUR CHARACTERISTICS		20 PATIENTS
Histology	IDC IDC + DCIS	16 4
Lymph node status	N+ N-	11 9
Molecular Tumor Subtypes	TRIPLE NEG HER-2 LUMINAL B LUMINAL A	11 5 3 1
Ki- 67	>30% ≤30%	16 4
Necrosis	NO YES* (foci) YES (central necrosis)	13 3 4

LA RIBERA
DEPARTAMENTO DE SALUD

Qualitative Parametric λ1 Map

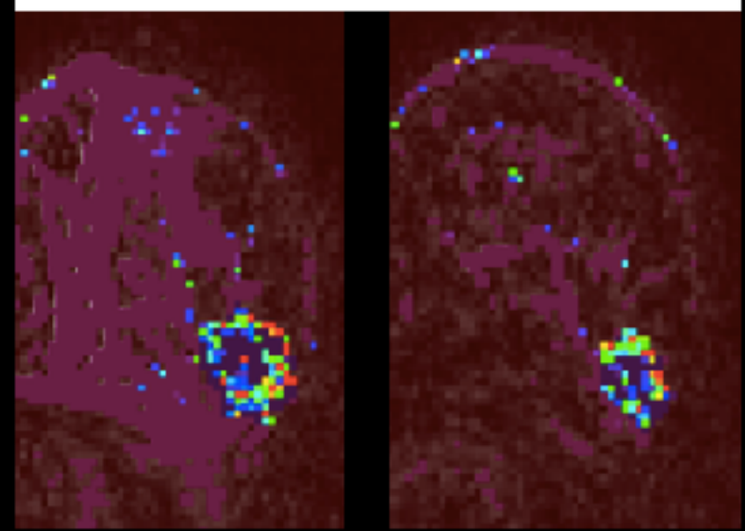

Quantitative λ1 Map ADC

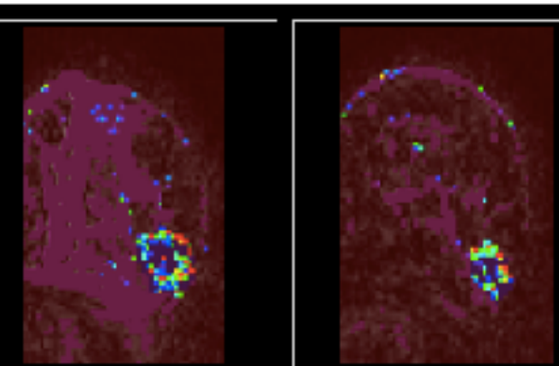

ADC 1,90 x 10^{-3} mm^2/s

ADC 1,12 x 10^{-3} mm^2/s

Response / No response (Lesions)

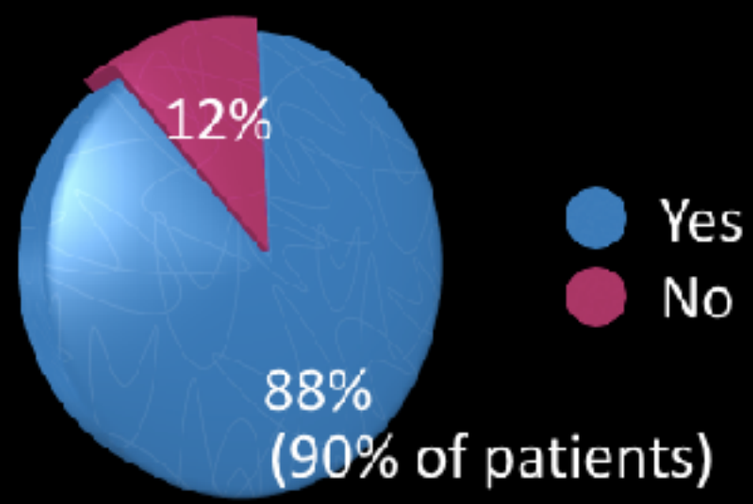

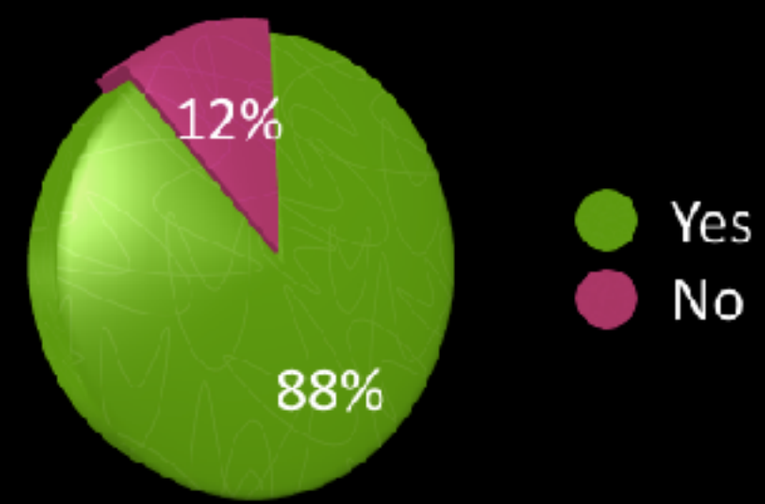

Exact type of response (Lesions)

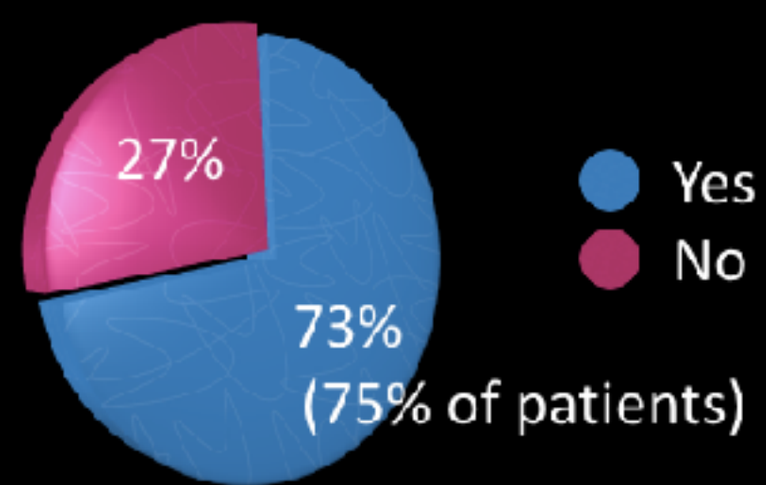

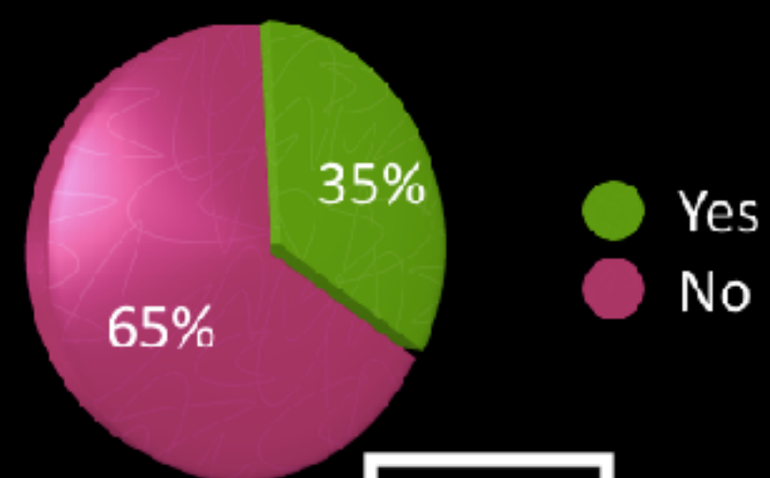

LA RIBERA
DEPARTAMENTO DE SALUD

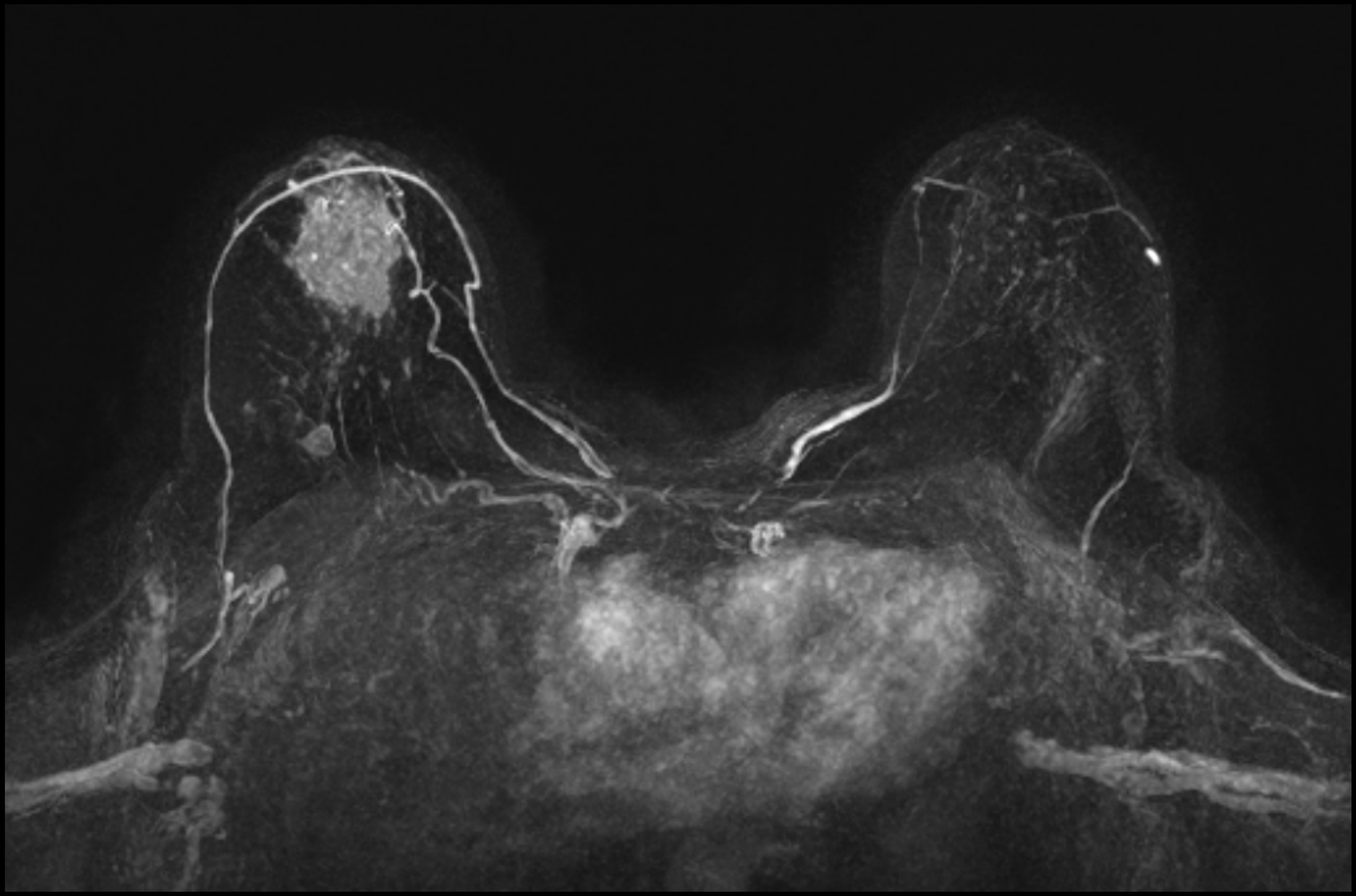

Baseline

Early after C2

RP menor funcional
No respuesta morfológica

ADC ↑ 17%

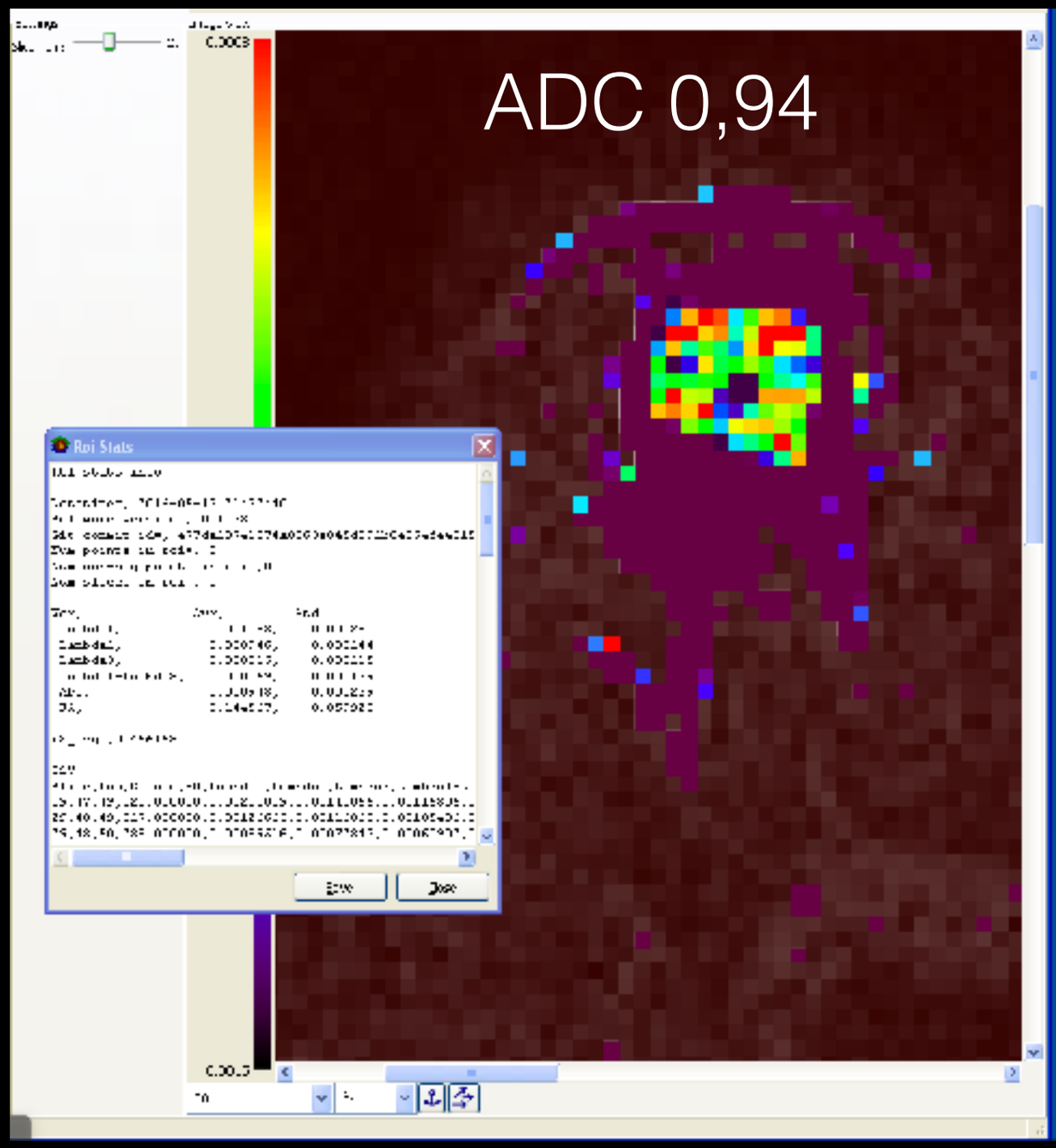

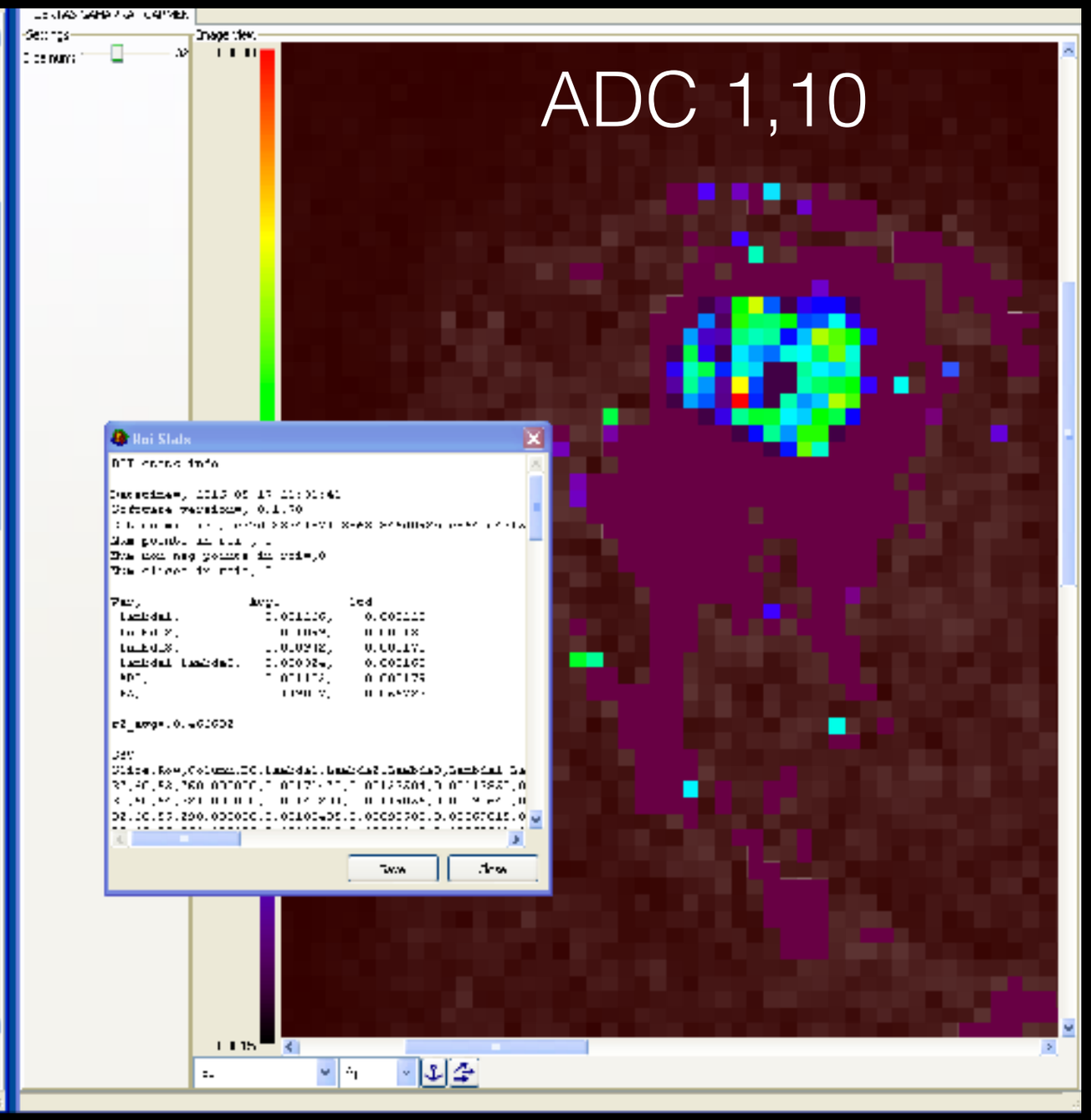

Baseline

Early after C2

55 pacientes - Valoración precoz de respuesta (C2)

<table>
<tr><th>RM/AP</th><th>RC</th><th>RP</th><th>NR</th><th>ProgT</th></tr>
<tr><td>RC (36%)</td><td colspan="2" rowspan="2">80% predice respuesta</td><td colspan="2" rowspan="2">7% sobreestimación
(3 TN 1 HER2)</td></tr>
<tr><td>RP (49%)</td></tr>
<tr><td>NR (14%)</td><td colspan="2">12% infraestimación
(2 TN 3 HER2 2 LUM)</td><td></td><td></td></tr>
</table>

CC en 35% de las pacientes

Conclusiones

- La RM multiparamétrica permite el análisis morfológico y funcional
  - de los fenotipos tumorales,
  - de la heterogeneidad tumoral
  - de la respuesta precoz a la neoadyuvancia
- Proporciona biomarcadores de imagen con potencial predictivo para modular tratamiento y abordaje quirúrgico.
- Futuro: radiogenómica

Muchas gracias